

MSK PATHOLOGY REVIEW

INITIATIVES
INNOVATIONS
ACCOMPLISHMENTS



Memorial Sloan Kettering
Cancer Center

2ND QUARTER
2018

COMMENTARY FROM THE DEPARTMENT CHAIR

Postgraduate Pathology Education at MSK: History and Prospects

This issue of the *MSK Pathology Review* includes an article on the history of pathology at MSK, written by Hope Cristol and Marc Rosenblum and filled with interesting details about the giants of pathology who preceded us. The training of pathology fellows has also been a critical part of the history of our department for more than 70 years, and all of the fellowship groups dating back to 1948 are captured in the photographs hanging in the Cytology corridor in our department. Our educational philosophy – to immerse the fellows in oncologic pathology material, with them taking the primary role in handling and reporting the cases, has been consistent throughout our history, but there have been significant changes in the training program over the past few decades including the addition of numerous subspecialty fellowship positions.

When I came to MSK in 1991, the structure of the oncologic surgical pathology fellowship had been unchanged for decades. This fellowship was our only substantial training experience at that time, and my addition at the last minute increased the number of fellows from 11 to 12. The fellows' rotations were simple: 10 months of surgical pathology, 1 month of autopsy, and 1 month for vacation. On the surgical pathology rotation, teams of three fellows would gross on the first day, read their slides on the second day, and sign out with the attendings on day three. Then repeat ad nauseum. Fellows were not actively involved in frozen sections, and departmental consult cases were dropped by the clinicians (who at that time came to the department to review these slides with us) into a large red box that sat on the enormous, slate, communal

sign-out table in the middle of the busy work room. These cases were designated “red box” cases and were reviewed ad hoc by the sign out teams who were already engaged in reviewing biopsies and surgical cases. The atmosphere was chaotic but oddly relaxed, and clinicians filtered in and out, accessioners screamed “*FROZEN SECTION*” when a case was ready for the frozen team to engage, and fellows sat studiously at the side of the attendings, adjusting their written reports based on more learned feedback. Prior to the arrival of Juan Rosai, sign out was conducted using single headed microscopes; if a fellow was uncertain why an attending had modified her diagnosis, she was free to retain the slides to study them privately after sign out was completed. This first major change in this routine came when Dr. Rosai arrived, as he was determined to introduce dedicated rotations for frozen sections, his personal consults, and elective project (and double-headed microscopes!). To accomplish this, we modified the three-day rotation to a two-day system, in which the fellow would return to grossing following the morning sign out. The gross room at that time measured about 8-foot square, with three fellows sitting at low tables and placing their tissue sections into reusable metal cassettes, along with a scrap of paper on which the case number and cassette designation were scrawled. If the case had a frozen section, the fellow had to leave the gross room to read the frozen section diagnosis from the massive book where these were recorded, which lived permanently in the frozen section area across the sign-out room from the gross room. When the slides were prepared by the histology lab, they were arranged

on 18X24 wooden trays, each containing multiple cases, for delivery to the fellows and review. Some of these trays persist in the department today, as they are indeed handy for transporting large numbers of slides. But beware! Tipping these trays too much can lead to an avalanche of glass, scrambling the cases at a minimum and shattering the slides at worst.

Within a few years of my arrival at MSK, modifications to the fellowship began. As the case volumes increased, more fellows were added – first bringing the number to 15 and then 17, where it remains today. Grossing became increasingly burdensome, due to the high volume and increasingly complex protocols for gross examination. Initially, a “gross room assistant” was hired to aid with specimen flow, help perform lymph node dissections, and undertake more routine grossing tasks. But by the early 2000s, multiple pathology assistants (PAs) were hired, and within just a few years, the majority of the grossing was performed by PAs. These dedicated and well-trained professionals do an outstanding job and helped standardize our protocols and approach, compared to fellows coming from a dozen different residency programs. Furthermore, the task of grossing specimens was not viewed as highly educational by prospective applicants to our fellowship, and we realized that maintaining our conviction that the gross evaluation provides essential diagnostic information (I still firmly believe this) was causing us to lose candidates before they ever visited our department. Thus, grossing is now largely going the way of electron microscopy and argyrophil stains (with apologies to Lars Grimelius, who is still alive and Emeritus Professor at Uppsala

University), at least from the perspective of fellowship training. But luckily the excellent work of our PAs means that we still derive all the diagnostically critical information from gross evaluations. The second major evolution in our program has been the proliferation of many additional specialty fellowship positions. Originally developed as selected second year research-focused fellowship, the surgical pathology subspecialty fellowships now encompass nearly every diagnostic discipline, and the clinical work has extended to involve these fellows as well. Additionally, training programs in molecular genetic pathology, cytology, hematopathology, and experimental pathology have all expanded, to the point that our current group of 40 fellows includes more subspecialty fellows (23) than oncologic pathology fellows.

So what is in store for the future of postgraduate pathology education at MSK? It is becoming increasingly clear that our traditional model, where essentially all clinical cases pass through the hands of a fellow, may not be sustainable as the institutional volume continues to expand. It is true that training in pathology requires exposure to a critical volume of case material, but it is equally true that there are many novel diagnostic tools at hand, and contemporary training requires that time be reserved to expose fellows to all aspects of diagnostic pathology. Increasingly, prospective fellows are looking for subspecialty training rather than broad surgical pathology exposure, and combinations of subspecialty fellowships with molecular diagnostics or research fellowships are becoming more attractive. In order for us to grow

with these changes, we must continually reevaluate our programs. The schedule we have today is enormously complex, but flexibility in training is a persistent request from our fellows. In order to become more creative with the fellowship programs, Kay Park (Director of Education), Melissa Murray (Fellowship Training Program Director), and Nora Katabi (Associate Fellowship Training Program Director) are working with our departmental administration to look for more efficient ways to handle the clinical material, with the idea that adding ancillary assistance in the process could alleviate the need for fellows (and attendings) to devote so much time to operational details. This would free us to consider more creative structuring of the training program. The addition of pathology residents is also under discussion, to give us the chance to influence young pathologists at an even earlier stage in their development, as well as to offer teaching opportunities to the fellows and hopefully groom some physician-scientists to spend time in our research labs. All of these modifications will require considerable work and creativity, but I think we must attend to them to keep us current with the needs of pathology trainees and ensure that MSK Pathology maintains its decades-long role in educating the very best practicing and academic anatomic pathologists. Creative suggestions are more than welcome!

- David Klimstra, MD

Redefining GYNECOLOGIC SARCOMAS

Sarah Chiang, MD, is making important contributions to GYN pathology, especially in uterine cancer.

By Hope Cristol



SARAH CHIANG, MD

For a pathologist who sees herself primarily as a clinician, Sarah Chiang, MD, takes on some surprisingly challenging research projects. One of her latest: exploring the molecular abnormalities that underpin uterine sarcomas.

“There is incredible morphologic overlap among various uterine sarcomas,” says Dr. Chiang, who signs out gynecologic and urologic pathology cases at MSK. “Morphology unfortunately doesn’t cut it anymore, and we need molecular genetics to help us refine tumor classification and improve clinical management.”

Genetic abnormalities, particularly fusions resulting from gene rearrangements, are found in a variety of uterine mesenchymal tumor types, including endometrial stromal sarcomas. While historically, gene fusions have not been associated with distinctive morphologic features, recent discoveries including those made by Dr. Chiang identify high-grade sarcomas with unique genotypes and phenotypes.

“Molecular diagnostics has dramatically changed patient care in all areas, but particularly in hematopathology as well as bone and soft tissue pathology,” Dr. Chiang says. “I want to bring that on board as part of the routine diagnostic evaluation of gynecologic lesions, particularly, uterine sarcomas. Even at MSK, we sometimes have difficulty diagnosing unusual lesions. We need novel diagnostic biomarkers and therapeutic targets for these women with rare sarcomas.”

Her recent work includes identification of novel types of high-grade endometrial stromal sarcomas harboring ZC3H7B-BCOR fusions and BCOR internal tandem duplications as well as NTRK fusion-positive uterine spindle cell sarcomas resembling fibrosarcoma.

In addition to her research on fusion discovery, she is also developing a methylation-based uterine sarcoma classifier that may assist in the diagnosis of tumors that are difficult to classify or predict behavior.

“All of this would not be possible without the unique collaborative environment we have at MSK,” says Dr. Chiang. “Through collaborations with Drs. Cristina Antonescu, Marc Ladanyi, Robert Soslow and Britta Weigelt, we are able to make great discoveries in the realm of uterine sarcomas.”

3 HIGHLIGHTS FROM USCAP

In case you missed Dr. Chiang’s presentations at the 2018 U.S. and Canadian Academy of Pathology (USCAP) conference in Vancouver, these are some of the highlights:

1 Platform Presentation: A Newly Defined Entity of High-Grade Endometrial Stromal Sarcomas

- ZC3H7B-BCOR fusion was confirmed in 17 tumors, including some previously diagnosed as myxoid leiomyosarcoma and undifferentiated uterine sarcoma.
- ZC3H7B-BCOR endometrial stromal sarcoma constitutes a distinct subtype with high-grade morphology.

2 Platform Presentation: Classifying Undifferentiated Uterine Sarcomas

- Many undifferentiated uterine sarcomas are under-recognized, high-grade endometrial stromal sarcomas with known gene fusions.
- BCOR immunohistochemistry with FISH and/or targeted RNA sequencing may aid in accurate classification of undifferentiated uterine sarcomas.

3 Poster: Novel PLAG1 Gene Rearrangement in Uterine Myxoid Leiomyosarcoma

- Novel PLAG1 rearrangements resulting in PLAG1 expression occur in approximately 25% of myxoid leiomyosarcoma and may serve as a useful biomarker for tumor classification.

SMART PURSUIT

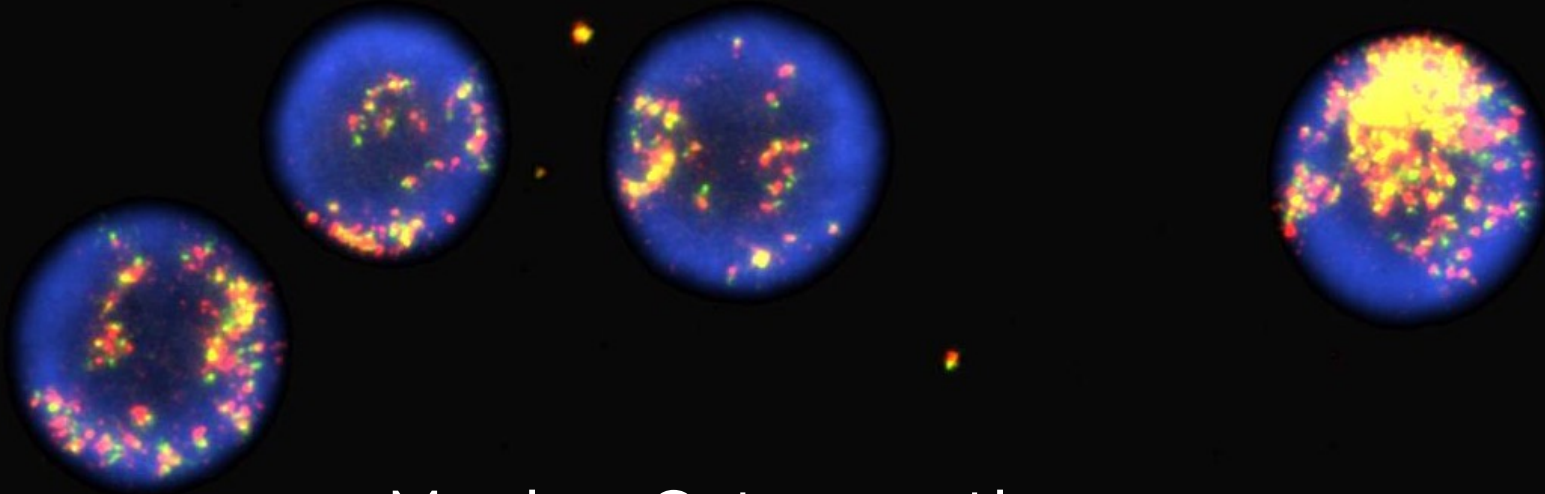
GYN pathology is evolving. “It’s been, historically, morphology-based diagnoses. That is going to change significantly as molecular diagnostics becomes incorporated in disease classification and management,” Dr. Chiang says.

She plans to be part of the change, putting her early training to good use so that more women with rare tumors can get answers and, hopefully, better treatments.

Dr. Chiang completed her residency in Anatomic Pathology and the Robert E. Scully fellowship in gynecologic, obstetric, and urologic pathology at the Massachusetts General Hospital in 2012. Surprisingly, exposure to molecular diagnostics was very limited. “Our residency molecular rotation was only three weeks long out of the entire three years of anatomic pathology training,” Dr. Chiang says.

She felt it was insufficient for an aspect of pathology that crosses all subspecialties. So, she took a two-month elective in molecular pathology “to gain more experience and time at the bench performing and interpreting the various assays in the clinical lab.”

Nearly five years into her career as an attending at MSK, Dr. Chiang says, “I incorporate much of that knowledge into what I do today on both clinical and research fronts.”



Moving Cytogenetics **FORWARD**

Cytogenetics Lab Director Yanming Zhang, MD, is passionate about the field and its future at MSK.

By Hope Cristol

Complex karyotype with loss of the short arm of chromosome 17, double minutes and MYC amplification in a patient with AML.

FISH analysis using MYC break-apart probes shows skyline colorful multiple signals all over the interphase nuclei, confirming the double minutes are MYC amplification in chromosome format, which is associated with poor prognosis in AML.

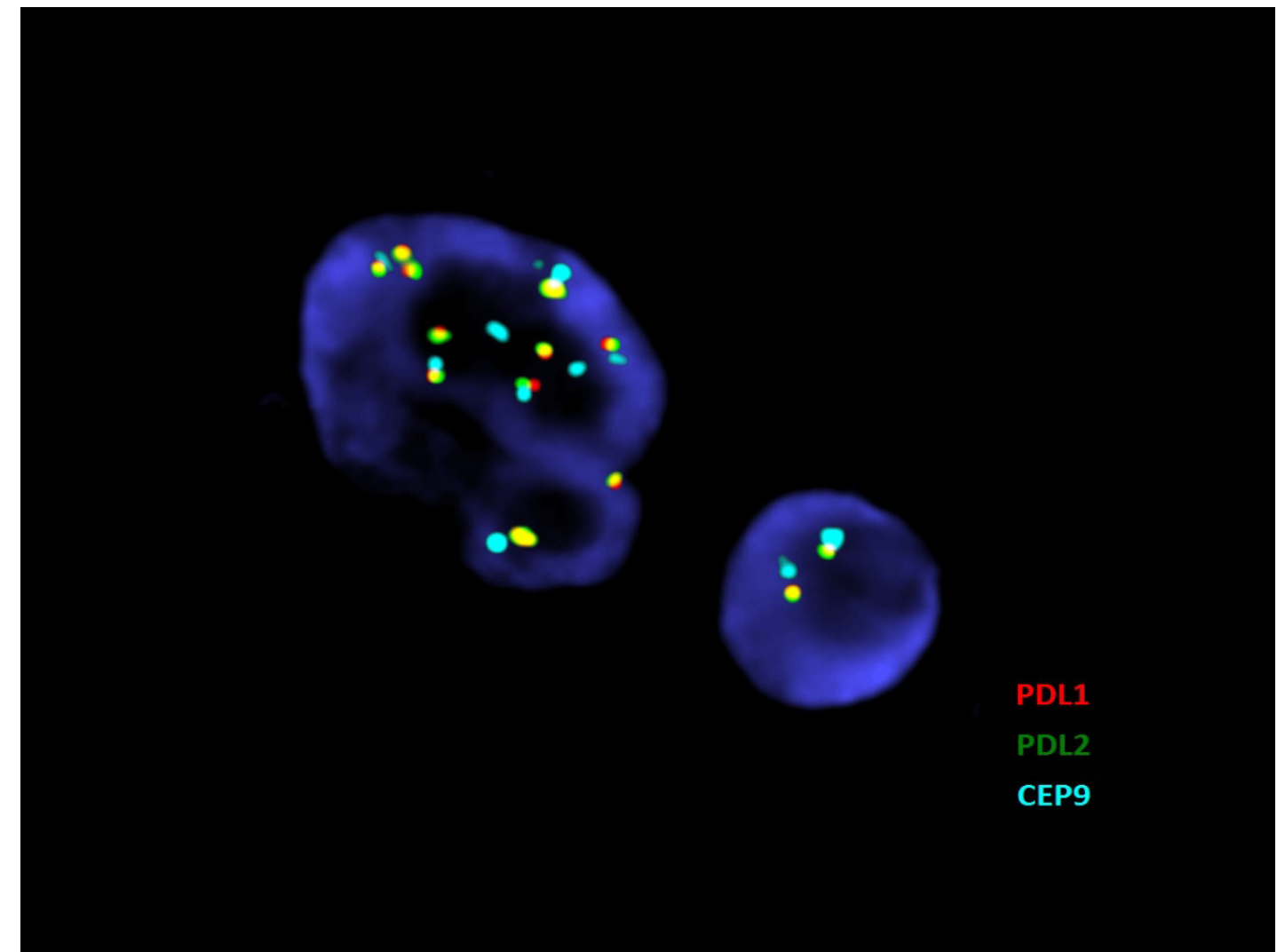
Cytogenetics, which looks at how chromosomes relate to cell behavior, has a relatively long history in pathology. "Cytogenetics has been in practice for more than 50 years, so all the results and their significance have been very solidly confirmed for clinical usage," says Yanming Zhang, MD, Director of the Cytogenetics Laboratory.

However, the tools and value of this subspecialty have evolved over time, keeping pace with the dramatic changes in the field of pathology. "In the early days of cytogenetics, like the 1970s and 1980s, conventional chromosome analysis was the only test we had," Dr. Zhang says. "In the 1990s, FISH, or fluorescent in-situ hybridization, became available. Then in the early 2000s, microarray became available. Now we can use these tests together to offer more comprehensive genetic testing and better prediction for patient outcome and treatment selection."


Dr. Zhang, who oversees a Cytogenetics staff of more than 25 people, recently shared his insight on the current state and his future hopes for Cytogenetics at MSK.

Let's start with some basic questions. What diagnostic role does cytogenetics have?

Conventional chromosome analysis, FISH analysis and microarray study can find abnormalities that are helpful for diagnosis, prognosis and treatment selection. Many chromosome abnormalities are uniquely associated with subtypes of leukemia, lymphoma and solid tumors. Some abnormalities are associated with good prognosis. Others, unfortunately, are associated with poor outcome and these patients may need more treatment or even clinical trials. Thus, detection of chromosome abnormalities also provides important prediction of treatment response.



FISH analysis of a patient with classical Hodgkin Lymphomas (cHL) showing amplification of PD-L1 and PD-L2 in a Hodgkin and Reed/Sternberg (HRS) cell. PD-L1 and PD-L2 are labeled with orange and green color, respectively. The CEP9 centromere probe is labeled with aqua. The HRS cell with bizarre nucleus shows multiple copies of PD-L1 and PD-L2 as well as CEP9.



A metaphase spread cell shows complex chromosome abnormalities, including gain of chromosome 4, abnormalities of chromosome 8 and 9, an isochromosome 17q (arrow), and numerous double minutes (arrows).

When would a sample go to your lab?

In most cases, cytogenetics is part of multiple pathologic analyses. For example, if a patient comes in with anemia and the physician wants to know if the patient has leukemia, a bone marrow aspirate would be drawn and sent to multiple laboratories in Pathology, including Cytogenetics. In a certain scenario, cytogenetic analysis may find abnormalities that determine the diagnosis before other tests can. If we find a clone by chromosome analysis, even if we are only looking at two cells, it may establish a diagnosis.

Can you describe a unique or challenging case?

Recently a lymphoma case with typical features of Burkitt lymphoma was received in the Cytogenetics Lab. We performed FISH analysis but found no evidence of the characteristic chromosome abnormality, t(8;14)/IGH-MYC fusion. We applied microarray analysis and detected a partial gain of the long arm of chromosome 11. This established the diagnosis of Burkitt lymphoma with 11q gain, the new entity that was just included in the new WHO lymphoma classification in 2016.

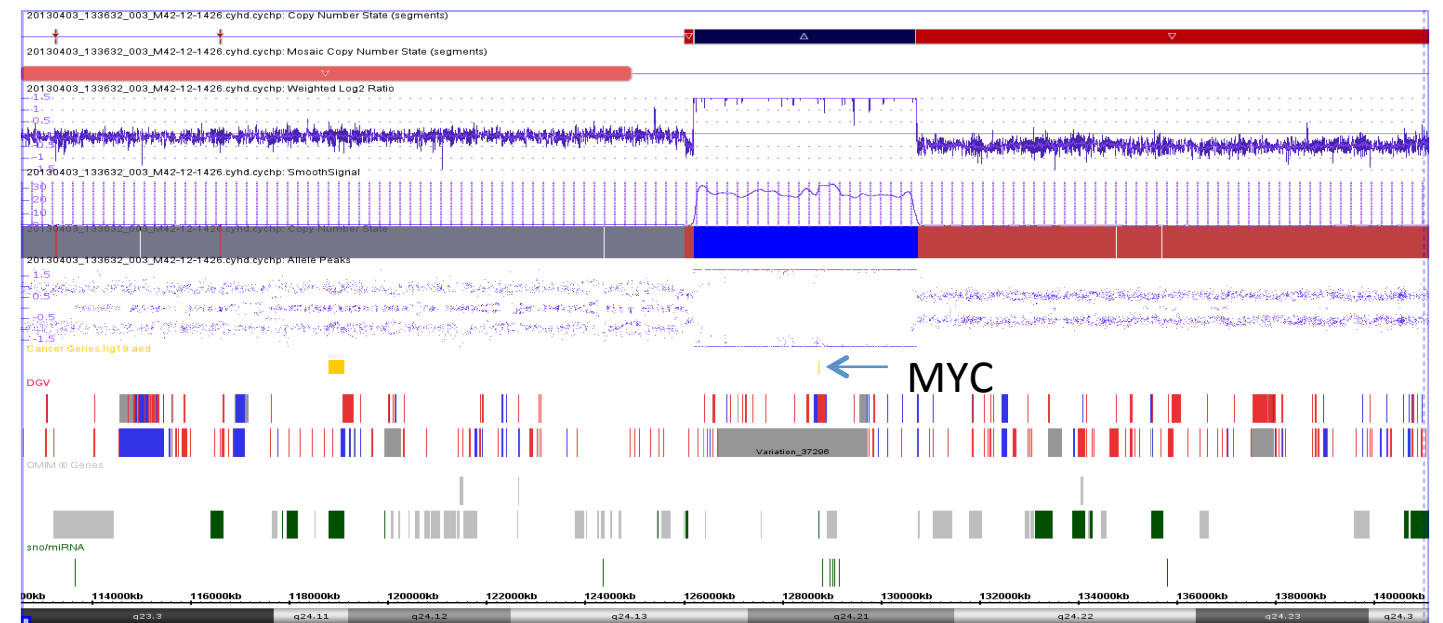
How does the Cytogenetics Lab support research at MSK?

Despite advantages of molecular genetics tests, Cytogenetics remains critical in discovering novel genetic biomarkers,

clarifying prognostic significance and integrating with other pathology results. Many researchers from the clinical side seek our support. With a large cytogenetic data resource, we have been working with our leukemia colleagues on correlating unique chromosome abnormalities, such as 11q23/MLL translocations, or complex karyotype with TP53 deletion and mutations with gene mutation profiles and clinic outcomes in various leukemia patients. We also work closely with our Hematopathology faculty and fellows on defining novel genetic biomarkers and new lymphoma entities. In solid tumor areas, we continuously bring in new FISH assays to confirm and detect novel genetic abnormalities that are diagnostic or prognostic.

What do you hope to accomplish at MSK?

I believe the future of cytogenetics has to be integrated with molecular techniques. We already have a good setting of three genetic laboratories within the Molecular Diagnostics Service under Dr. Marc Ladanyi's leadership. We may work together by triaging samples and deciding the most appropriate tests to perform, particularly if the specimen is limited, to provide the maximum genetic information for the need. We can share our resources and help each other with our analysis and interpretation. With advanced NGS techniques and excellent experience in cancer cytogenetics, we can be pioneers in correlating and integrating these fields.




Genomic microarray tests revealed multiple complex chromosomal gains and losses on chromosomes 4, 8, 9, and 17. Amplification at 8q24 was observed, with copy numbers up to 36, including the MYC gene (arrow).

MEET YANMING ZHANG, MD

Dr. Zhang joined MSK in October 2016 as Director of the Cytogenetics Laboratory. His formal medical education began in China, continued in Germany and concluded with a fellowship at the University of Chicago. He stayed on faculty at UChicago for several years, advancing his career and the field of cytogenetics under the mentorship of the late Janet Rowley, MD, the geneticist best known for describing the Philadelphia chromosome as resulting from a reciprocal translocation between chromosomes 9 and 22.

Dr. Zhang was later recruited by Northwestern University's Department of Pathology to establish a new clinical cytogenetics laboratory and serve as its medical director. But, nearly six years later, he was offered a position at MSK. "I was very excited. Memorial Sloan Kettering is a very good place for advanced genetic practice, and I was interested in integrating cytogenetics with these new techniques," Dr. Zhang says.

He oversees routine clinical service, supports research and conducts his own research, especially in collaboration with the Leukemia Service and the Hematopathology Service. In addition, he is an active leader in the cytogenetics community. Since 2013, Dr. Zhang has been Chair of the Eastern Cooperative Oncology Group (ECOG) Leukemia Cytogenetics Committee, overseeing cytogenetics quality and results of multiple leukemia clinical trials from numerous cytogenetics laboratories.



Researching RARE HEAD AND NECK CANCERS

Nora Katabi, MD, hopes her work leads to better diagnosis and treatment of salivary gland tumors.

By Hope Cristol



NORA KATABI, MD

As a head and neck pathologist, Nora Katabi signs out rare cancer cases all the time. That's partly because Memorial Sloan Kettering Cancer Center (MSKCC) is a leader in diagnosing and treating rare diseases, and partly because head and neck cancers are uncommon to begin with, accounting for just 4% of all cancers in the U.S.

However, Dr. Katabi's academic

focus is even more specialized: She primarily researches salivary gland malignancies, which make up less than 1% of all cancers in the U.S. This rarity makes them difficult to study in general, but being at "a big center like MSKCC means I am fortunate to be able to see [relatively] many cases for our research," Dr. Katabi says.

The number of study cases is not

always sufficient to establish statistical significance, she notes, but she's hopeful that her research in the pathologic and molecular classification of salivary gland tumors can eventually improve diagnosis and treatment. In her roughly 10-year career, which began as a fellow at MSK, she has published numerous studies advancing the understanding of this rare cancer.

“The translocation can separate clear cell carcinoma of the salivary gland from other salivary gland tumors.”

COLLABORATIVE DISCOVERIES

One example of an important research effort - with Chief of Experimental Pathology Jorge Reis-Filho, MD, PhD - could ultimately establish a new target for therapy.

"I have worked with Dr. Reis-Filho on the characterization of polymorphous adenocarcinoma of the salivary glands," she says. It's the second most common type of malignancy in the minor salivary glands. Drs. Katabi, Reis-Filho and others identified a kinase-activating alteration (PRKD1 hotspot mutations) as a likely driver of this cancer.

Early in her career, Dr. Katabi worked with Cristina Antonescu, MD, Director of Bone and Soft Tissue Pathology, to describe an EWSR1-ATF1 fusion in hyalinizing clear-cell carcinoma, a rare, low-grade salivary gland malignancy. The discovery is important because several salivary gland carcinomas have histological overlap, presenting a diagnostic challenge. "This translocation

can separate clear cell carcinoma of the salivary glands from other salivary gland tumors," Dr. Katabi says.

Some of her most recent research is on myoepithelial carcinoma, which is an under-recognized, rare, aggressive salivary gland cancer with largely unknown genetic features. In collaboration with MSK surgical oncologist Luc Morris, MD, Dr. Katabi and other researchers comprehensively analyzed molecular alterations in 40 cases. A brief look at their findings, published last October in *Nature Communications*:

- Myoepithelial carcinoma is low in mutations, high in oncogenic gene fusions
- Most fusions involve the PLAG1 oncogene, associated with PLAG1 overexpression
- FGFR1-PLAG fusions were found in seven (18%) cases
- The novel TGFBR3-PLAG1 fusion was found in six (15%) cases.

Thus, the researchers concluded that myoepithelial carcinoma is fusion-driven, suggested that the TGFBR3-PLAG1 is a hallmark of the disease, and provided a framework for future diagnostic and therapeutic research.

"This special entity, myoepithelial carcinoma, is close to my heart," Dr. Katabi says. "I've learned so much about it." She's now researching the consequences of misdiagnosing this rare entity as benign.


BUILDING A DATABASE FOR HEAD AND NECK CANCERS

Dr. Katabi is also working to build a database of salivary gland tumor cases. The database would include many of her own contributions, including detailed analysis of the histopathologic features of several salivary gland tumors.

Of course, she hasn't embarked on this project alone. Like all great things to come out of the Pathology Department, this is a joint effort to classify the tumors and analyze their clinicohistologic and molecular features in detail. Dr. Katabi is working with the Head and Neck team, especially Ronald Ghossein, MD, Director of Head and Neck Pathology, and the Head and Neck clinicians and researchers. She's hopeful the database can be used to advance future studies and projects.

Of the many papers that Dr. Katabi has co-authored, including phase I and phase II treatment studies, these are a few that have been published over the past year:

- 1 *Head & Neck*: "Patterns of recurrence in oral tongue cancer with perineural invasion."
- 2 *Oncotarget*: "Detection of HPV related oropharyngeal cancer in oral rinse specimens."
- 3 *Human Pathology*: "Salivary gland epithelial neoplasms in pediatric population."
- 4 *Histopathology*: "PLAG1 immunohistochemistry is a sensitive marker for pleomorphic adenoma: a comparative study with PLAG1 genetic abnormalities."
- 5 *Nature Communications*: "Multi-dimensional genomic analysis of myoepithelial carcinoma identifies prevalent oncogenic gene fusions."



HISTORY OF PATHOLOGY AT MSK

Snapshots – in words and pictures – from the events and people that forged the foundation of the Pathology Department.

By Hope Cristol
and Marc Rosenblum, MD

When it comes to the people and circumstances that have shaped the Department of Pathology at Memorial Sloan Kettering Cancer Center (MSK), there are several important truths:

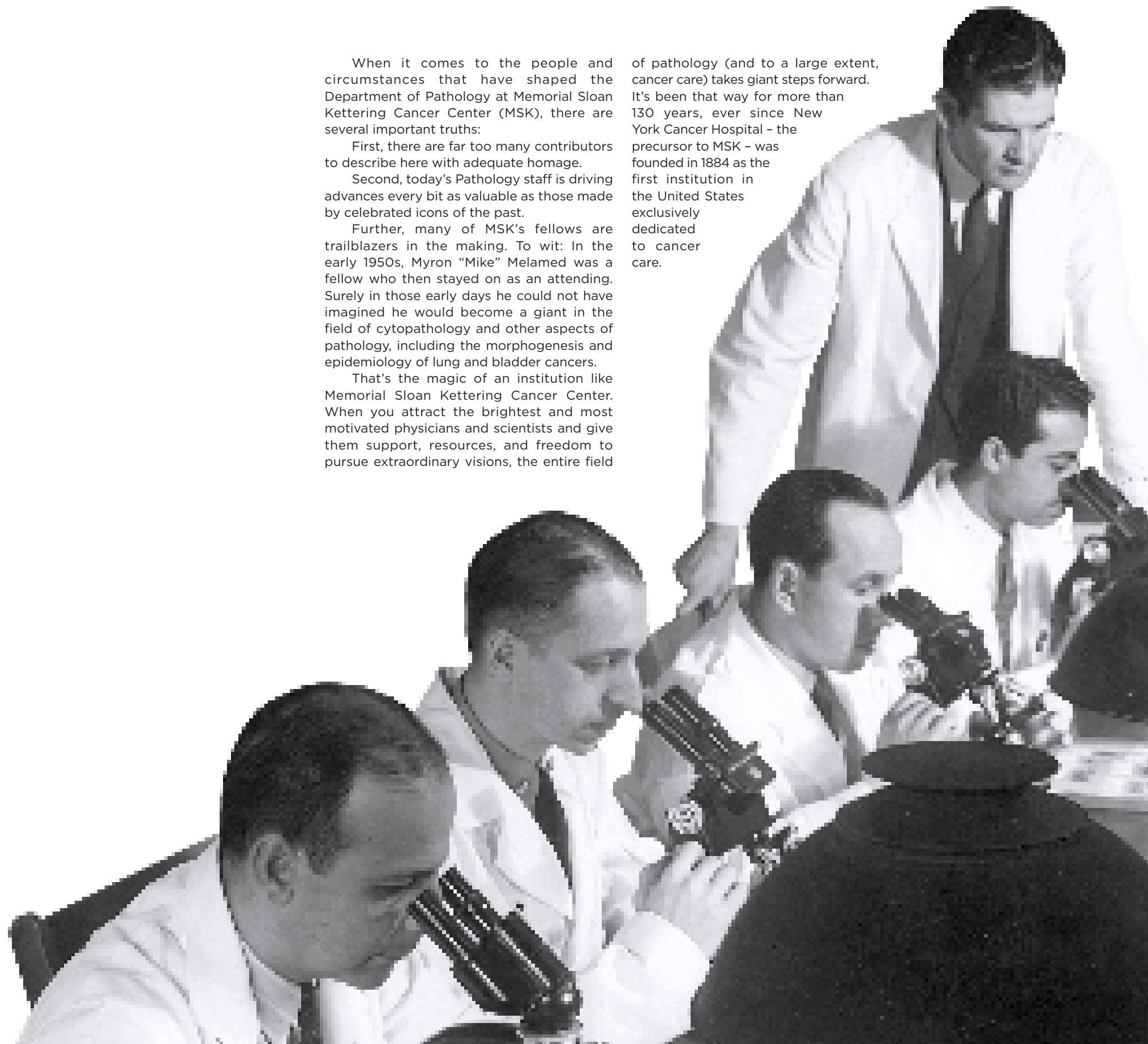First, there are far too many contributors to describe here with adequate homage.

Second, today's Pathology staff is driving advances every bit as valuable as those made by celebrated icons of the past.

Further, many of MSK's fellows are trailblazers in the making. To wit: In the early 1950s, Myron "Mike" Melamed was a fellow who then stayed on as an attending. Surely in those early days he could not have imagined he would become a giant in the field of cytopathology and other aspects of pathology, including the morphogenesis and epidemiology of lung and bladder cancers.

That's the magic of an institution like Memorial Sloan Kettering Cancer Center. When you attract the brightest and most motivated physicians and scientists and give them support, resources, and freedom to pursue extraordinary visions, the entire field

of pathology (and to a large extent, cancer care) takes giant steps forward. It's been that way for more than 130 years, ever since New York Cancer Hospital – the precursor to MSK – was founded in 1884 as the first institution in the United States exclusively dedicated to cancer care.



THE PIONEERS

George Cornell Freeborn, who graduated from Columbia University's College of Physician's & Surgeons in 1873, was the first pathologist at the New York Cancer Hospital. During the hospital's first year in operation, Dr. Freeborn examined 55 specimens under the microscope. The following year, it was 86.

Dr. Freeborn was well versed in major diagnostic entities and able to identify a range of benign and malignant tumors. This established the hospital as a diagnostic authority from the start.

The public, however, generally feared cancer and did not embrace the institution's exclusive mission. And so, in 1898, the hospital's first major shift occurred. Cancer care was scaled back; general hospital functions were added. The name changed, too, from New York Cancer Hospital to General Memorial Hospital for the Treatment of Cancer and Allied Diseases.

"The very concept of a medical institution dedicated to the treatment of neoplastic diseases was born of the fact, now incredible to contemplate, that patients known or suspected to be suffering from cancer were generally not welcome in the hospitals of the day," says MSK Neuropathology Director and Autopsy Service Chief Marc Rosenblum, MD, known to Pathology colleagues as the department's resident historian.

Dr. Rosenblum adds that the initial proposal for the New York Cancer Hospital is attributable to physician J. Marion Sims, who previously established the Women's Hospital of New York. Considered the founder of modern surgical gynecology, he is lauded for many achievements, including developing a procedure to successfully repair vesicovaginal fistulas. (Unfortunately, his legacy became tainted decades after his death, based on controversial allegations that Dr. Sims' early vesicovaginal fistula surgeries were performed on slave women who were not in a position to give proper informed consent.)

At the Women's Hospital, Dr. Sims had been reprimanded by the Board of Managers for admitting and operating on patients whom he suspected to have cancer. "Board members worried, as did many people at the time, that cancer might be a contagious disease and, in any event, thought that the presence of women doomed to die of cancer could only cause distress to other patients," Dr. Rosenblum says. "Sims resigned from the hospital he had himself created and lobbied for the realization of what would eventually become MSKCC."

Meanwhile, the march of progress in medicine continued. Pathologists wrote books, performed autopsies, took academic positions, and traveled near and far to study under leading physicians. Among the field's rising stars was James Ewing, who became the first professor of pathology at Cornell University Medical School in 1899, a position he held until 1932.

Dr. Ewing formed an alliance with prominent mining engineer James Douglas, PhD, then president of the Phelps Dodge Corporation. He was an advocate of the therapeutic potential of radium, discovered in 1898, even after it failed to save his daughter from breast cancer. After her death in 1910, Douglas dedicated his life to promoting "radium therapy" for cancer, and formed the National Radium Institute to mine the substance from uranium ores in Colorado.

Together, Drs. Ewing and Douglas made a proposition to General Memorial Hospital. In exchange for restoring the institution's focus to cancer care, and committing to radium research and treatment for cancer, Dr. Douglas would donate both money and radium. Dr. Ewing would become president of the medical board, director of research, and pathologist to the hospital. The hospital accepted.

Before long, Dr. Douglas made additional donations and Dr. Ewing became the hospital's director, a position he held from 1931 to 1939. Among his writings, Dr. Ewing authored *Neoplastic Diseases*, which anchored his position as the preeminent authority on the diagnostic pathology of human

tumors. His leadership in the field and at the hospital helped establish Memorial as a leading, if not the leading, free-standing cancer center in the world.

Though, of course, there have been many contributors to the institution's excellence in pathology, it can be said that in the earliest years, these two helped launch pathology's rise to prominence here.

OTHER NOTEWORTHY FIGURES FROM THE OLD GUARD

There's practically encyclopedic breadth and depth of information about the history of pathology at MSK. It dovetails, naturally, with the history of pathology in general, as well as scientific innovations. Here is a brief, and by no means comprehensive, look at influencers from the "old guard" - well before the 1960s.

Elise Strang l'Esperance: Dr. l'Esperance, who was particularly interested in early cervical cancer, joined Dr. Ewing in 1916 at Memorial Hospital. She was a proponent of the cervicovaginal smear technique for cancer screening and a firm supporter of Papanicolaou.

In 1943, she donated two Technicon tissue processors to the Pathology Department. In 1945, she established at Memorial Hospital and the New York Infirmary two Strang Prevention Clinics. The first clinical cytology lab, established at the Strang Clinic, would become the Cytology Service of the Department of Pathology.

Fred Stewart: Dr. Stewart became Ewing's assistant in 1927 and head of the Pathology Department in 1939. He was renowned for his diagnostic excellence. Stewart's consultations were brief, to the point, and highly sought out, particularly for problem cases. (He typed all his own personal and professional correspondence on an Underwood typewriter, which sat on a metal stand on wheels.)

The American Cancer Society would eventually recruit

DIAGNOSES POST-WWII

Do you take for granted the relative ease of obtaining tumor material? Needless to say the early days weren't so clean (literally). After World War II, aspiration smears were used to diagnose tumors, mostly from palpable breast lesions. They were stained with hematoxylin and eosin, and arranged on large, wooden trays. They were also, relative to today's specimens, abysmal: bloody, thick, poorly spread, and overstained.

Dr. Stewart as Founding Editor of the journal *Cancer*, which appeared in 1948 as the first periodical devoted solely to studies in the pathology, pathogenesis, and treatment of neoplastic diseases. The first edition included articles co-authored by Dr. Stewart that established the criteria for the diagnosis of post-radiation sarcomas, and that defined the entity of lymphangiosarcoma arising in the setting of post-mastectomy lymphedema (Stewart-Treves syndrome).

Dr. Stewart and his students described a number of other tumor entities and he produced *Tumors of the Breast* (1950), the first Armed Forces Institute of Pathology (AFIP) Fascicle devoted to mammary neoplasia.

August Wadsworth: Head of the Division of Laboratories and Research at the New York State Department of Health in Albany, he approached Drs. Stewart and Ewing for help improving the performance of other pathology labs across the state. This was during the 1930s, and board certification for pathology would not become common until the 1960s.



MSK CHAIRMAN
Timeline

JAMES EWING, MD
1913-1939

FRED STEWART, MD
1939-1959

FRANK FOOTE, JR., MD
1959-1972

PATRICK J. FITZGERALD, MD
1972-1979

MYRON "MIKE" R. MELAMED, MD
1979-1989

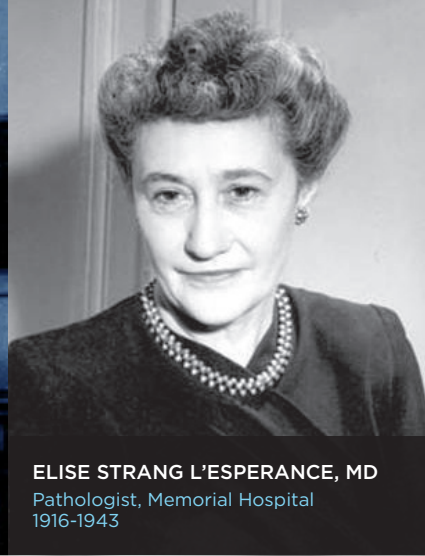
JUAN ROSAI, MD
1991-1999

MARC K. ROSENBLUM, MD
2003-2010

BORIS BASTIAN, MD, PHD
2010-2011

DAVID S. KLIMSTRA, MD
2012-Present

WOMEN IN PATHOLOGY AT MSKCC



ELISE STRANG L'ESPERANCE, MD
Pathologist, Memorial Hospital
1916-1943

ELISE STRANG L'ESPERANCE, MD

The first clinical laboratory of cytology, established at the Strang Cancer Prevention Clinic, subsequently became the Cytology Service of the Department of Pathology.

SOPHIE SPITZ, MD

Spitz produced the monumental, beautifully illustrated atlas, *Pathology of Tropical Diseases*.

Her term "juvenile melanoma" became synonymous with her name and was renamed "Spitz nevus".



SOPHIE SPITZ, MD
Pathologist, Memorial Hospital
1939-1942 and 1945-1949

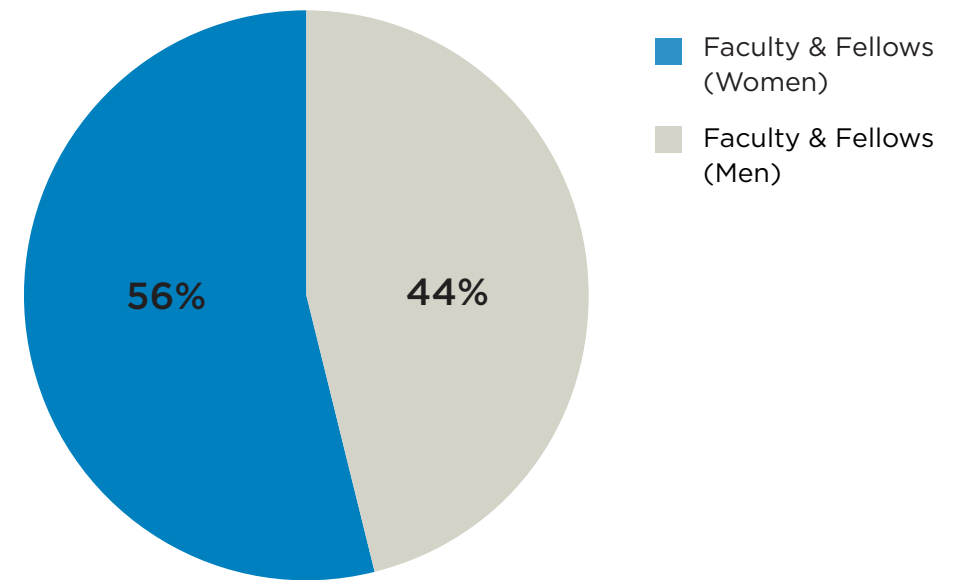
MEERA HAMEED, MD
Chief, Surgical Pathology Service

MARIA ARCILA, MD
Director, Diagnostic Molecular
Pathology Laboratory

RYMA BENAYED, PHD
Director, Clinical Next Generation
Sequencing Laboratory

JESSICA CHAPMAN-LIM, PHD
Director of Clinical Proteomics
Hematopathology Service

MSKCC DEPARTMENT OF PATHOLOGY: FACULTY & FELLOWS (MEN & WOMEN), 2018





CHRISTINE IACOBUZIO- DONAHUE, MD PHD
Associate Director for Translational Research,
David M. Rubenstein Center for Pancreatic
Cancer Research Sequencing Laboratory

KAY PARK, MD
Director of Education, Department of
Pathology
Vice Chair, Graduate Medical Education
Committee

BRITTA WEIGELT, PHD
Director, Gynecology Research
Laboratory

MARIKO YABE, MD PHD
Director, Bone Marrow
Laboratory

YUKAKO YAGI, PHD
Director, Pathology Digital Imaging



LIYING ZHANG, MD PHD
Director, Diagnostic Molecular
Genetics Laboratory

CRISTINA ANTONESCU, MD
Director, Bone and Soft Tissue
Pathology

EDI BROGI, MD PHD
Director, Breast Pathology

JINRU SHIA, MD
Director, Gastrointestinal Pathology
Director, Gastrointestinal Pathology Fellowship
Program Laboratory

MELISSA MURRAY, DO
Program Director, Oncologic Surgical
Pathology Fellowship

Learn more about the history of women in our department and their profound achievements and contributions in our 1Q19 issue.

*Faculty featured in this section hold a "Director" title

Drs. Stewart and Ewing would help Wadsworth establish a system of state approval for county laboratories: The pathologist-in-charge had to document proficiency by rendering diagnoses on a set of 100 histologic slides prepared at Memorial.

Frank W. Foote, Jr: He joined the department as a National Cancer Institute Fellow and ultimately became Stewart's successor as head of the Pathology Department. Drs. Stewart and Foote established sign-out routines for the first time, a practical method to cope with the soaring volume of material in surgical pathology after World War II (about 17,000 in 1946).

Dr. Foote was a gifted diagnostician and produced, among many notable works, *Tumors of the Major Salivary Glands* (1954). It was co-authored with head and neck surgeon Edgar Frazell and the first AFIP Fascicle devoted to lesions of this type.

Sophie Spitz: The Spitz nevus was named for this part-time pathologist at Memorial. She originally termed the childhood skin lesion "juvenile melanoma" in a 1948 paper. However, it would come to be closely associated with her and eponymously renamed.




STORIED ARCHITECTURE

Even the physical structure of MSK has an architecturally significant and storied past. The original building, located on the corner of 106th Street and Central Park West in Manhattan, was inspired by a French chateau. Four large, conical towers each housed beds in a circular fashion, in part to improve surveillance of the patients. At least according to lore, a displeased public called it the "Bastille of Central Park."


In 1939, the hospital moved to a new building at 444 East 68th Street, built on land donated by John D. Rockefeller Jr. In 1948, The Sloan-Kettering Institute (SKI) opened on adjacent land. This research arm of the hospital was established thanks to the vision of hospital director Cornelius P. "Dusty" Rhoads and the generosity of Alfred P. Sloan and Charles F. Kettering.

It would be another 12 years before the institution took on its current name and function. In 1959, the combined hospital and research institute were named Memorial Center for Cancer and Allied Diseases. Finally, in 1960, Memorial Sloan-Kettering Cancer Center was incorporated, with SKI and the hospital as its two major entities.

IN MEMORY




ANDREW HUVOS, MD
1934-2006




WILLIAM GERALD, MD, PHD
1954- 2008




DANIEL FILIPPA, MD
1940- 2011



MYRON "MIKE" MELAMED, MD
1927-2013



JAMES M. WOODRUFF, MD
1937-2015



PHILIP LIEBERMAN, MD
1924-2015


**“As is a tale,
so is a life:
Not how
long it is, but
how good
it is, is what
matters.”**

- Seneca



Ladies' Board of the New York Women's Hospital established

1866




Hospital name changed to the "General Memorial Hospital for the Treatment of Cancer and Allied Diseases"

1898



First World Series


1917



Dr. James Ewing becomes the pathologist for the General Memorial Hospital for the Treatment of Cancer and Allied Diseases

1913


Drs. James Douglas and James Ewing propose a permanent affiliation with Cornell in exchange for a gift of \$100,000, several grams of radium (then worth \$100,000/gram), equipment to set up an X-Ray treatment facility and clinical laboratory.



JAMES EWING, MD
1913-1939



1871

First pathology laboratory established at Roosevelt Hospital



1887

106th Street location opens as the "New York Cancer Hospital"



1895

Formalin fixation proposed by TS Cullen at Johns Hopkins



Hospital name changed to "Memorial Hospital for the Treatment of Cancers and Allied Diseases"



US enters WWI



John D. Rockefeller offers an annual donation of \$60,000 to "enhance teaching efforts at Memorial Hospital"



Augustus Wadsworth (head of the Division of Labs and Research at the New York State Department of Health in Albany, NY) approaches Drs. Ewing and Stewart for assistance in establishing a system of state approval and support for county laboratories.

1916

Dr. Elise Strang l'Esperance joins the Pathology Department

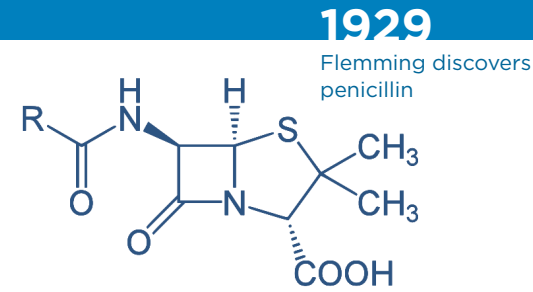


1917

Laboratory established on premises




1927



1931

Dr. James Ewing is featured on the cover of Time Magazine



Amelia Earhart flies across the Atlantic Ocean



1932



Dr. Frank Foote joins the department as a fellow



Introduction of immunohistochemistry at MSKCC

1938

New location at 444 East 68th Street is opened



1939

Dr. Fred Stewart is appointed Chairman of the Department of Pathology



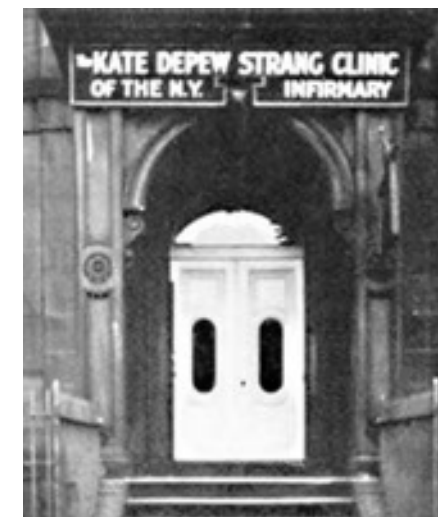1941

US enters WWII




1945

Dr. Elise Strang l'Esperance establishes two Strang Cancer Prevention Clinics which later become the Cytology Service in the Department of Pathology




FRED STEWART, MD
1939-1959



Research arm of hospital established as the "Sloan Kettering Institute"

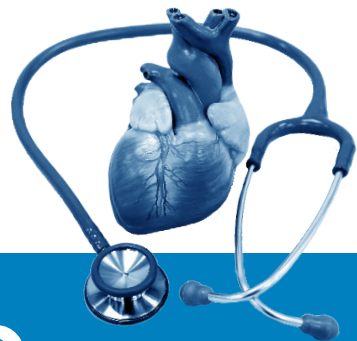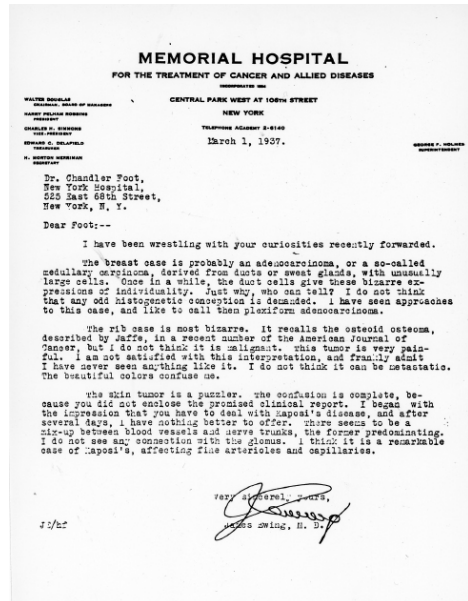
1948

Journal *Cancer* is published which is sponsored by the American Cancer Society. Dr. Fred Stewart serves as Editor.



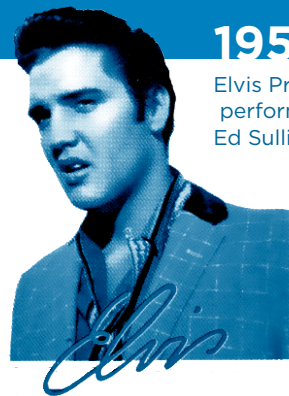
1950

Combined centers are named "Memorial Center for Cancer and Allied Diseases"



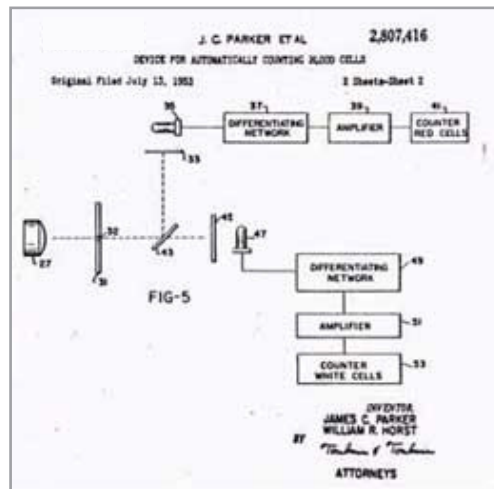
First open heart surgery

1952



1956

Elvis Presley performs on the Ed Sullivan Show



Establishment of flow cytometry at MSKCC

1957

1960

NY Board certification in pathology and cytology with proficiency exams established with the help of Memorial Hospital Pathology staff.



President John F. Kennedy assassinated

1963



1964

Civil Rights Act of 1964



FRANK FOOTE, JR., MD
1959-1972



Introduction of the electron microscopy at MSKCC

1965



Neil Armstrong walks on the moon

1969

Cytotechnology training program, first established in the early 1950's, is officially recognized as the School of Cytology under the leadership of Dr. Leopold Koss and Mrs. Grace Dufree.



PATRICK J FITZGERALD, MD
1972 - 1979



President Nixon resigns

1974

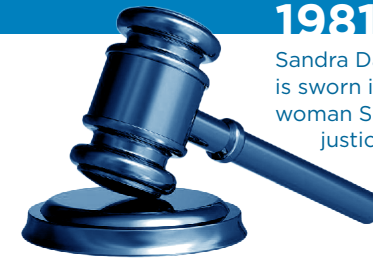1973

Main Campus location opens at 1275 York Avenue




Introduction of biobanking at MSKCC

1976



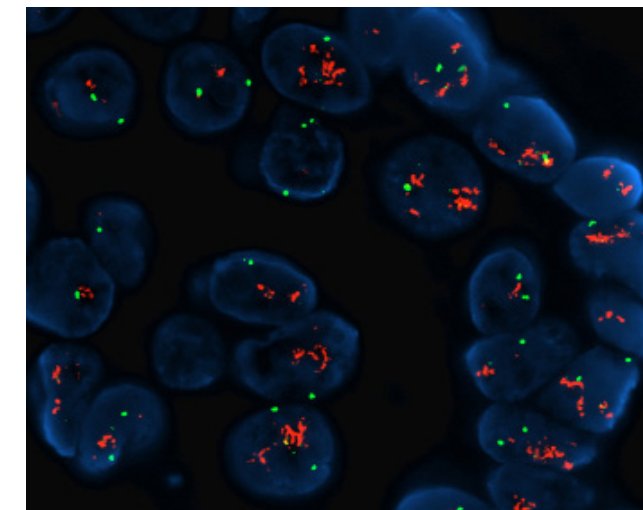
1981
Sandra Day O'Connor is sworn in as the first woman Supreme Court justice.



2001
Scientists develop a method that combines microarray technology with a form of artificial intelligence which enables physicians to tell the difference between four childhood cancers — neuroblastoma, Ewing's sarcoma, non-Hodgkin lymphoma and rhabdomyosarcoma.

1985

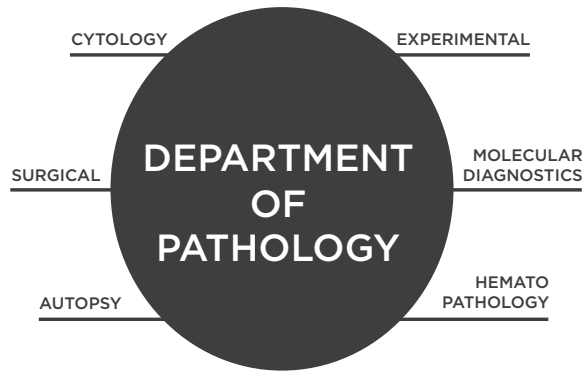
FISH (fluorescence in situ hybridization) introduced



MYRON "MIKE" MELAMED, MD
1979 - 1989



JUAN ROSAI, MD
1991 - 1999




Establishment of surgical pathology



The American recession begins



Introduction and utilization of telemedicine and telecytology



FNA Biopsy Clinic opens



Establishment of the PPBC (Pathology Precision Biobanking Center)

2004



Facebook is launched

2005


Establishment of the Molecular Diagnostic service



2008

2015

Introduction of digital pathology



2016

2017


Establishment of the Warren Alpert Center



MARC ROSENBLUM, MD
2003-2010



BORIS BASTIAN,
MD, PhD
2010-2011



DAVID KLIMSTRA, MD
2012-Present



“ Their scientific impact cannot be overstated. In due time, it is likely that each of them will be extensively celebrated and memorialized in the literature of pathology.”

the *New England Journal of Medicine* that confirmed the association between smoking and lung cancer.

One of his most significant, pioneering contributions to cytometry was his seminal 1965 paper in *Science*, titled “Spectrophotometer: New Instrument for Ultra-rapid Cell Analysis.” Dr. Melamed (along with his friend at Columbia University, Louis A. Kamentsky) described the first flow cytometer that provided multiparameter analysis. Specifically, ultraviolet absorption and visible light scatter were measured simultaneously, enabling the display of two-dimensional histograms. The instrument, developed in an effort to measure the DNA ploidy of cells, became the basis for the next generation of flow cytometers.

“Dr. Melamed was an exemplary physician-scientist. While directing a remarkably far-sighted research program in quantitative and automated cytology, he took his regular turns with the rest of the staff on the Surgical Pathology and Cytology Services. He was a skilled diagnostician and teacher,” Dr. Rosenblum says. “More than a few owe the launching of their academic careers to Dr. Melamed, who effectively placed the future of genitourinary pathology at MSKCC in the hands of a young Victor Reuter and who challenged me to reinvent myself as a neuropathologist.”

Dr. Melamed passed away in 2013 of pancreatic cancer – though he beat the long odds for a while, surviving with the devastating disease for more than six and a half years.

Juan Rosai. Our institution was fortunate to have Dr. Rosai serve as Department of Pathology Chair from 1991 to 1999. He is the author or coauthor of numerous publications and other important works, including *Rosai and Ackerman’s Surgical Pathology*, the *2nd Series AFIP Fascicle on Tumors of the Thymus*, and the *3rd Series AFIP Fascicle on Tumors of the Thyroid*. He is also the editor of the Second Edition of the W.H.O. book on *Histologic Classification of Thymic Tumors*, as well as editor of the book *Guiding the Surgeon’s Hand: The History of American Surgical Pathology*.

Other career achievements include the characterization of rare medical conditions. These include desmoplastic round-cell cancer and a type of histiocytosis known as Rosai-Dorfman disease. Despite his obviously demanding and rigorous schedule, he managed to serve as a wonderful mentor to many, and today is known for that as well.

MODERN LEGENDS

If you’re outside the Department of Pathology, you may be unfamiliar with the names Mike Melamed, Juan Rosai, Philip Lieberman, Stephen Sternberg. Inside the department, it’s a vastly different story. Around here, indeed across the entire field of pathology, they are legendary.

These and several other pathologists (along with a few others, including Drs. William Gerald and Willet Whitmore) made extraordinary contributions to pathology during their time at MSK. They also mentored some of today’s department leaders, including Dr. Rosenblum; Pathology Chair David Klimstra, MD; Pathology Vice Chair Victor E. Reuter, MD; and Molecular Diagnostics Service Chief Mark Ladanyi, MD.

Their scientific impact cannot be overstated. In due time, it is likely that each of them will be extensively celebrated and memorialized in the literature of pathology. For the purposes of this brief history, however, these here are a few some career highlights of a few of the icons of the second half of the 20th century and just beyond.

Myron “Mike” Melamed. Those who knew Dr. Melamed can probably list, offhand, many of his major roles and achievements. He was Chair of the Pathology Department from 1979-1989, a founding member of the International Society for Advancement of Cytometry, a co-editor of the first monograph *Flow Cytometry and Sorting*, President of the American Society of Cytology, and one of the co-authors on a 1990 study in



J. MARION SIMS, MD



JAMES DOUGLAS, MD



ELISE STRANG L'ESPERANCE, MD



FRED STEWART, MD

PATHOLOGY LEGENDS



AUGUST WASDWORTH, MD



FRANK W. FOOTE, JR., MD



SOPHIE SPITZ, MD



MYRON "MIKE" MELAMED, MD



WILLIAM GERALD, MD, PhD



JUAN ROSAI, MD



MARC ROSENBLUM, MD



DAVID KLIMSTRA, MD



VICTOR REUTER, MD



MARC LADANYI, MD



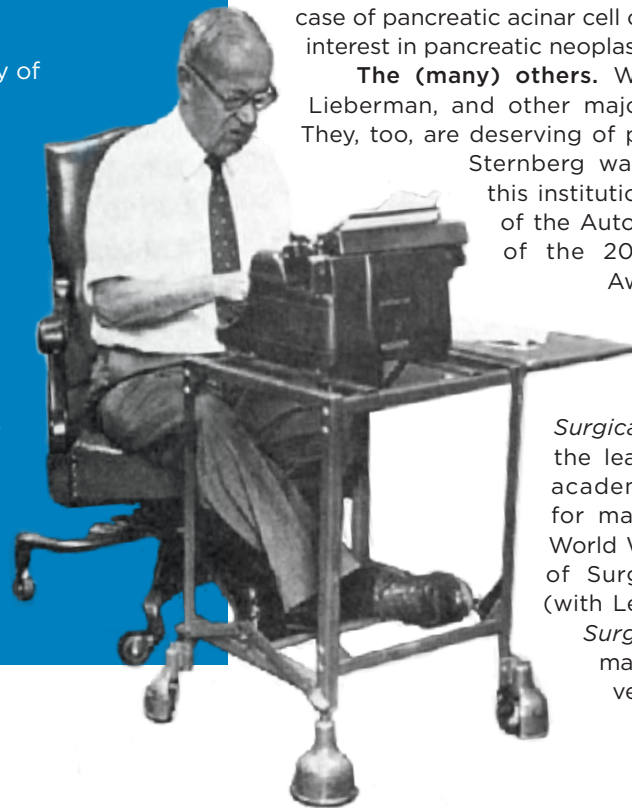
STEPHEN STERNBERG, MD



PHILIP LIEBERMAN, MD

FRED STEWART, MD

- Son of the City Attorney for the city of Binghamton, NY
- Prominent member of the Cornell Chamber Music Group
- Fluent in French
- 1 finger typist
- Never had a secretary at MSKCC
- Famously very interested in politics with often unpopular views of FDR
- Loved to travel via cargo ship
- Connoisseur of antiques



the US Armed Forces Institute of Pathology. During and after this study, Dr. Klimstra was struck by the dearth of American pathologists studying pancreatic cancer, and he decided to help fill in the gap. Remarkably enough, that single uncommon case of pancreatic acinar cell carcinoma in 1989 sparked an interest in pancreatic neoplasia that continues to this day.

The (many) others. What about Drs. Sternberg, Lieberman, and other major influencers on the field? They, too, are deserving of pages not available here. Dr. Sternberg was a surgical pathologist at this institution for nearly 50 years, Chief of the Autopsy Service, and a recipient of the 2001 Fred Waldorf Stewart Award for his contributions to progress against human neoplastic diseases. He was also Founding Editor of *The American Journal of Surgical Pathology*, which became the leading publication venue for academic surgical pathologists for many years. Dr. Lieberman, a World War II veteran, was the Chief of Surgical Pathology, co-author (with Leopold Koss) of *Guiding the Surgeon's Hand*, and author of many papers on both human and veterinary pathology.

These and many other past leaders in our Pathology Department have not only helped shape pathology as we know it today, but also groomed - directly and indirectly - the pathologists who are making history at the microscope right now.

Editorial Acknowledgements: Mary Ann Friedlander, Drs. Achim Jungbluth, David Klimstra, Victor Reuter and Marc Rosenblum

In an interview with *The Pathologist*, Dr. Klimstra recalls how Dr. Rosai influenced his decision to focus on pancreatic neoplasia many years ago.

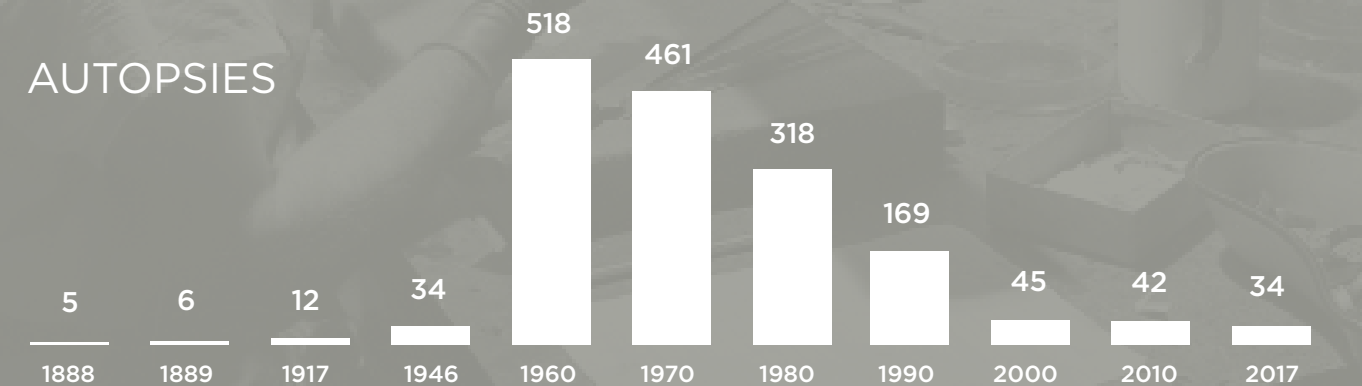
When Dr. Klimstra was a resident at Yale, he encountered a rare case of pancreatic acinar cell carcinoma. Back then it required electron microscopy to confirm the diagnosis. Dr. Rosai had told him there were no immunohistochemical markers for it, and certainly no comprehensive studies on it, so he encouraged Dr. Klimstra to assemble a series of cases and review the collection of

SPECIMENS REVIEWED & AUTOPSIES VOLUME GROWTH 1888-2017

SPECIMENS

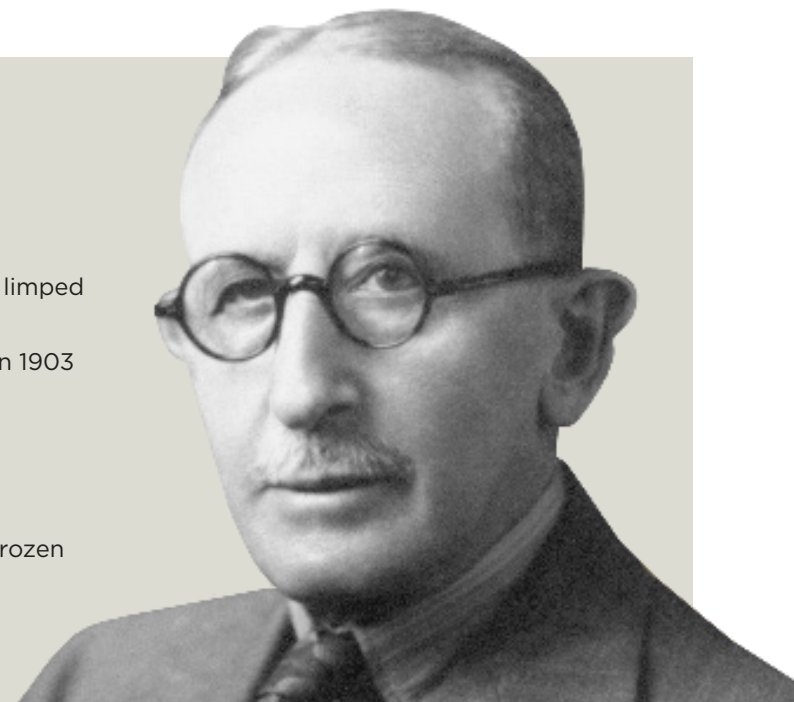


AUTOPSIES



JAMES EWING, MD

- Born on Christmas Day
- Son of a judge and school teacher
- Suffered a bout with osteomyelitis and as a result limped until his death
- His wife, Catherine Crane Halstead, passed away in 1903 from toxemia in her second pregnancy
- Had one son, James "Jimmy" Ewing, Jr.
- In 1943 he diagnoses his own bladder cancer
- "Ewing's Sarcoma"
- Famously had major reservations in reference to frozen sections



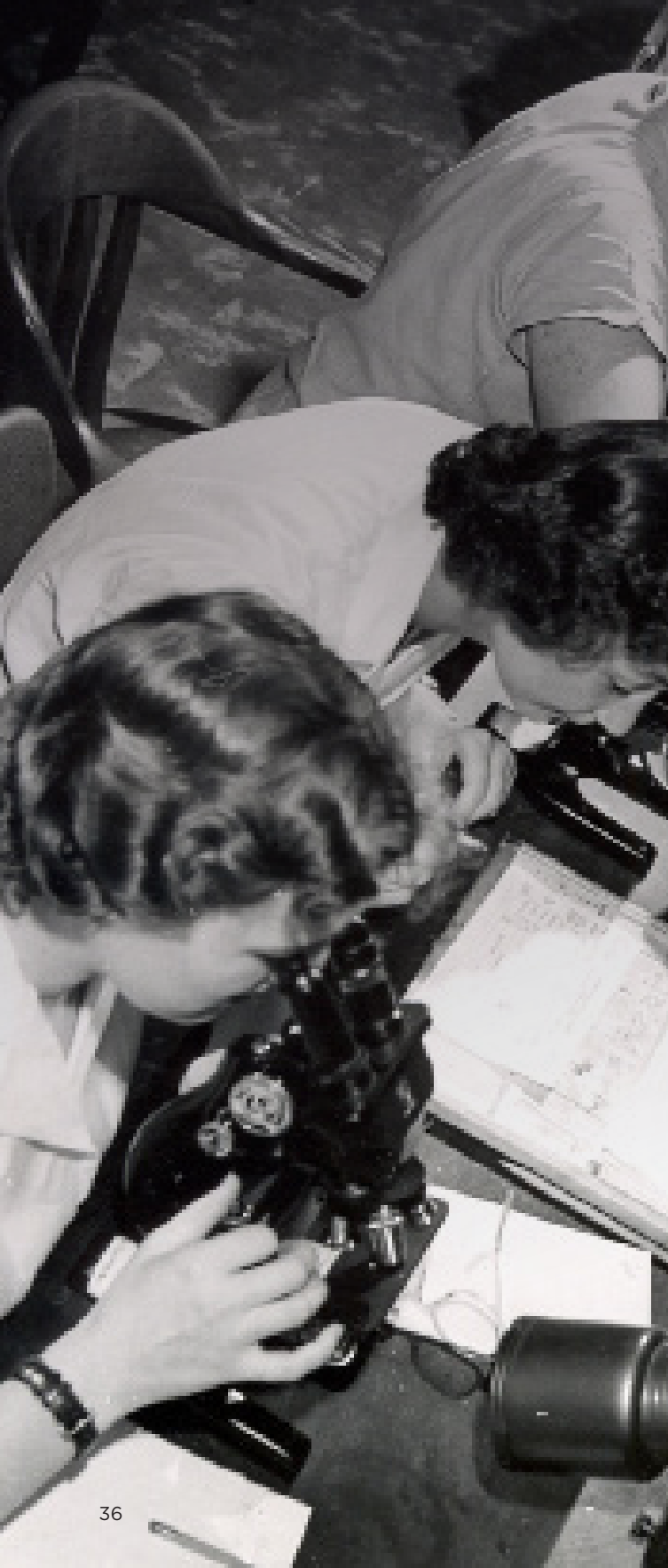MORE THAN PATHOLOGISTS

The Department of Pathology's recent leaders weren't just brilliant. They were also fun, and there are pictures that capture some of the joyful moments when they were around.

In one, Dr. Sternberg smiles for the camera while holding a small goat. In another, Drs. Reuter, Lieberman, Sternberg, Melamed, and Rosenblum scrunch side-by-side on a couch, their arms around each other. And there's this classic: Dr. Rosai bowing to kiss Dr. Reuter's hand as the men practiced protocol for meeting the Pope.

These snapshots may not characterize their clinical or research impact, but they reveal a fun and collegial mood in their presence - and that is certainly part of the history of Pathology at MSK.

MSK Pathology THROUGH THE YEARS



REPORT OF THE PATHOLOGIST.

To the Medical Board of the New York Cancer Hospital :

GENTLEMEN—During the year ending December 31, 1888, I have had referred to me for microscopical examination fifty-five (55) specimens. The diagnoses founded upon the examinations are given in the following table :

Carcinoma (schirrus) of the breast	27
“ of the gluteal lymph nodes	1
“ of the uterus	3
“ of the ovary (cyst wall)	1
Sarcoma of the breast	1
“ of the uterus	1
“ of the ribs	1
Intracanalicular fibroma of the breast	2
Adenoma of the breast	1
Papillary adenoma growing into a cyst of the breast	1
Epithelioma of the nose	1
“ of the uterus	1
“ of the cervix uteri	8
Fibroma of the ovary	1
“ of the breast	1
Cyst of the breast	1
Chronic mastitis	1
Lipoma	1
Dermoid cyst of the ovary	1
Total	55

The results of five autopsies are as follows :

Carcinoma (secondary) of the liver	1
Epithelioma of the scalp, bones of the skull, abscess of brain	1
General peritonitis following a slough of the sigmoid flexure, after laparotomy	1
Secondary sarcoma of the pleura, lungs, and liver	1
Carcinoma of the uterus, carcinomatous nodule occluding left ureter, dilatation of the ureter and pelvis of the kidney, chronic diffuse nephritis	1
Total	5

New York, January 1, 1889.

G. C. FREEBORN.

New York Pathological Society.

THE ANNIVERSARY MEETING of the Society will be held at the Academy of Medicine, 17 West 43d Street, on Wednesday, January 14th, 1903, beginning promptly at 8.30 P. M.

PROGRAM.

- | | |
|--|--|
| (1) A Case of Bothrioccephalus Anemia, with remarks on the Occurrence of Bothrioccephalus in America. By Dr. W. N. BERKELEY. | (6) on the Recognition of Dysentery, Typhoid, and Allied Bacilli; demonstrations. By Drs. P. H. BISS and F. P. RUSSELL. |
| (2) On the Nature and Origin of Blood-plates. By Dr. L. B. GOLDHORN. | (7) A Method of Separation of Colonies of Shiga's Bacillus from the Colon Bacillus. By Dr. E. K. DUNHAM. |
| (3) Demonstration of the Hemostatic Reaction in Corneal Vaccine Bodies. By Dr. JAMES EWING. | (8) On the Interpretation of Reactions of Agglutination among the Bacilli of Dysentery. By Dr. W. H. PARK. |
| (4) Limits of a Specific Reaction in the Serum Test for Blood. By Drs. JAMES EWING and ISRAEL STRAUSS. | (9) Relation of the Innervation of an Organ to the Influence of Suprarenal Extract upon it; with demonstrations. By Dr. S. J. MELTZER and Dr. CLARA MELTZER. |
| (5) A Study of a Bacillus Resembling the Bacillus of Shiga, from a Case of Fatal Diarrhoea. Remarks | |

EXECUTIVE SESSION: Reading of names of members delinquent for dues. Election of Officers.

J. C. WOOD, M.D., Secretary,
265 W. 57th Street.

JAMES EWING, M.D., President.



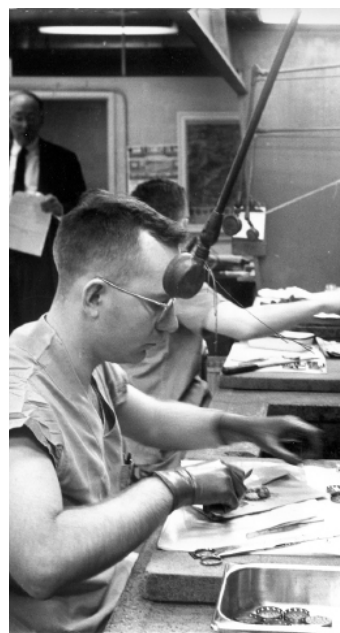PATHOLOGY DEPARTMENT - Residents and Staff 1983-1984


Back Row: Drs. Murakami, Garin, Filippa, Zaman, Rosen, Saigo


Middle Row: Drs. Urmacher, Cardon-Cardo, Huvos, Woodruff, Melamed, Epstein, Lieberman, Sternberg, Hajdu

Front Row: Drs. Reuter, Hebbard, Young, Lamoureux, Chess, Sanders, Jozefczyk, Purrazzella, Rosenblum, Haupt, Garcia, Wagner

Missing: Dr. Erlandson











Q&A

WITH MARY ANN FRIEDLANDER

Quality and Regulatory Manager



leadership to collect and monitor a variety of lab-defined quality metrics. This data includes specimen submission deficiencies, turnaround time, amended reports and diagnostic discrepancies. We track monthly metrics, investigate non-conformances and look for opportunities to enhance quality and patient safety.

We also facilitate internal and external laboratory inspections and work with lab management to address identified deficiencies, investigate non-conformances and ensure robust, effective corrective actions. We monitor corrective actions of citations from past inspections for continued effectiveness. Hopefully, when inspectors come to the laboratories, we will have minimal to no citations because we operate at continual readiness.

What other positions have you had at MSKCC?

I have been fortunate to have several opportunities to grow professionally here. I started as a student in the MSK School of Cytotechnology and stayed on as a staff cytotechnologist. I soon became the Education Coordinator of the school and enjoyed the combination of clinical work and

teaching cytotechnology to students and fellows. My interest in accreditation occurred when I was the Education Coordinator. Running a school extended beyond teaching. I learned the administrative requirements of a running a training program. I eventually moved on to become the Cytology Lab Manager. Managing laboratory operations was very different than teaching, but during this time, I realized I really enjoyed quality management and regulatory compliance. Eventually, the Quality and Regulatory Manager position arose in the department and allowed me to have an opportunity to work more closely in these areas.

Looking back on your 25+ years at MSK, what are some of your favorite parts of the work?

Working in cytotechnology was always stimulating. I enjoyed microscopic work, hunting for significant cells and correlating morphology with clinical information to determine the best diagnosis for the patient alongside the pathologist. I enjoy the fact that pathology has evolved so much. As an educator, you have to be on your toes when students ask questions and keep up with all the changes in the field.

In my current role, I enjoy event investigations and problem solving. I enjoy evaluating and simplifying complicated processes to make them

more efficient, without compromising quality or end results. I find it rewarding to work collaboratively with all lab staff at finding solutions and improving the quality of what we do.

Why is teaching so important to you?

Teaching is important to me because I love the challenge of getting someone to learn something that they may not have known before. I enjoy the challenge of recognizing different learning styles and modifying my teaching style to get to get the message across to the learner. I enjoy developing different educational resources to enhance the learning process. Making that connection is not always so easy and requires patience but when it is successful, it is very rewarding.

Are you still able to incorporate education in your current role?

Even though formal teaching is no longer my primary job, I try to

incorporate teaching in my current role. My team and I have presented several QA educational sessions on regulatory compliance topics, thematic QA events, quality improvement and internal and external inspections. Our hope in sharing this information is not only to engage and enlighten staff, but to gain their active involvement in developing and maintaining quality practices.

MSK is the kind of place where people tend to stay, yourself included. What has kept you here for so long?

I think if my first job in cytology were at a different institution, I probably would have gone back to school and likely be doing something else. MSK Pathology is an incredible place to work. Our case mix and the experts that I work with have all made for a fulfilling work experience. I am grateful that I have always had great mentors in every job I've had, who mirror what it is to grow professionally.

Outside of MSK, I also volunteer in several professional societies. This has provided me the opportunity to expand my knowledge beyond the microscope and acquire skills I wouldn't have otherwise gained sitting at my desk behind the microscope or computer all day. I have managed several projects, presented workshops, fostered professional relationships and continue to learn from colleagues at other institutions. This combined experience is what prepared me for each job at MSK.

Follow us on
TWITTER
@MSKPathology

THE EVOLUTION

of Genitourinary Pathology at MSK

By Hope Cristol

Yingbei Chen, MD PhD, Samson Fine, MD, Satish Tickoo, MD, Victor Reuter, MD, Hikmat Al-Ahmadie, MD, S. Joseph Sirintrapun, MD, Anuradha Gopalan, MD

Pathology Department Vice Chair Victor E. Reuter tips his hat to the giants who came before him and shares highlights of the all-star team today.

There are just a few pathologists who have worked in the Pathology Department for more than three decades. Victor Reuter, MD, is one of them. He is Vice Chair of the Department of Pathology, Team Leader of Genitourinary Pathology and Director of the Genitourinary Pathology Fellowship.

You'd expect Dr. Reuter to be a rich source of information about pathology at MSK – and he is. What may come as a surprise, though, is just how enthusiastic he is about it.

Dr. Reuter is energized by the achievements and possibilities of modern pathology. He's admiring of his colleagues' talent. He talks with reverence about his early years at MSK. And when Dr. Reuter describes the strategy behind building his genitourinary (GU) team, it sounds more like the NFL draft than pathology staffing.

Here, Dr. Reuter talks about the evolution of GU pathology at MSK, which

he was so instrumental in shaping.

EARLY INFLUENCERS

Dr. Reuter came to MSK as an American Cancer Society Fellow in Anatomic Pathology in 1983 without any specific intention to focus on GU pathology. It became his subspecialty by chance, largely because of the leaders and mentors around him.

At the time, the late Myron Melamed, MD, was Chair of the Pathology Department. He is known for his enormous contributions to the field of cytometry, and his work included research in flow cytometry in urothelial cancer.

When Dr. Reuter became chief fellow, his second year at MSK, he was tasked with urology grand rounds by the late Philip Lieberman, MD, Chief of Surgical Pathology.

During that time, he grew influenced

“These are the things that as a pathologist interest me the most – not only who needs systemic therapy but who can we actually treat more conservatively.”

by the late Willet Whitmore, MD, the Urology Service Chief who is known as the father of surgical urologic oncology. Dr. Reuter describes him as a renaissance man, a great surgeon, a great thinker, someone who made everyone around him feel necessary and important, and a true believer in team science.

“That trio of people exposing me to and pointing me toward GU pathology is how it became my area of interest and expertise,” Dr. Reuter says.

ESTABLISHING A TEAM

Eventually, Dr. Reuter became the only member of the Pathology Department focused entirely on GU cancers. He also became increasingly strapped for time as the volume of GU cases increased and the science of urologic oncology became more complex. Meanwhile, he was also supporting a vibrant research community in bladder, testis, prostate and kidney cancers.

“We realized we needed more people than just myself,” Dr. Reuter says. So began the years-long process of building his GU team. “For this, I have to thank my department chairmen, Dr. Rosai, Dr. Rosenblum and Dr. Klimstra. They allowed me to create the GU Pathology team in a manner that we had a shared vision for.”

The first hire was Satish K. Tickoo, MD, one of the original GU pathology fellows in the department. “He's a fabulous pathologist and has an encyclopedic knowledge of the literature,” Dr. Reuter says.

Then came Samson W. Fine, MD, who was trained at Johns Hopkins and has a passion for studying the prostate gland. He brought a sound foundation

in diagnostic pathology, which Dr. Reuter considers the bedrock of surgical pathology.

In the early 2000s, after scientists completed the Human Genome Project and interest turned towards the genomics of neoplastic diseases, pathology started to evolve faster than ever before. “There were all these new studies being done: new classifications, new molecular information, different therapeutic options. It really required a different type of pathologist,” he says.

KEEPING UP WITH A CHANGING FIELD

Dr. Reuter helped recruit pathologists with an interest in translational research to round out the GU team. The first of this group was Anuradha Gopalan, MD, who started at MSK as a fellow and then spent time in the lab of the late William Gerald, MD, PhD, working on prostate cancer. “She published seminal papers on aspects of molecular biology and clinical repercussions in prostate cancer,” Dr. Reuter says.

After her, Hikmat Al-Ahmadie, MD, joined the staff. A prior fellow in oncologic surgical pathology and GU pathology, “he went to practice at University of Chicago and then he came back as our bridge to the translational efforts in bladder cancer,” Dr. Reuter says.

Finally, Yingbei Chen, MD, became the team's bridge to kidney translational research. “She's produced seminal papers in that area and has developed a very good relationship with members of other departments focused on kidney cancer,” Dr. Reuter says.

It would seem the GU team was complete. Dr. Reuter felt it was strong diagnostically, in translational research and in collaborative relationships. There

was just one problem: the increase in clinical volume in one of the busiest subspecialties at MSK, comprising approximately 17% of all cases accessioned in pathology.

That's where the two part-time members of the GU team come in. GYN pathologist Sarah Chiang, MD, and Director of Pathology Informatics Joseph Sirintrapun, MD, both have training and interest in GU pathology, so they play an important role signing out cases on the GU team.

LOOKING AHEAD

After 35 years in the field and countless achievements, Dr. Reuter still does not feel he has come close to maxing out his interest in or potential for contributions to the field.

“What keeps things interesting is that on a weekly basis, we have additional information that comes to bear on our diseases. There are these subtle changes within classification, subtle changes in what assays we do to classify a tumor, or to establish risk or response to therapy,” Dr. Reuter says.

That last part – establishing which patients are best suited for a specific therapy – is the modern-day holy grail of pathology. “There are big efforts going on in our institution to try to address that at the molecular level, but I don't think we're close to solving the problem. That's aspirational.”

Dr. Reuter is looking for, and looking forward to, eventual answers to questions like: When can a renal tumor can be left alone and not necessarily resected? When is it that we don't need to give intravesical therapy for bladder cancer because we can predict that the chances of tumor progression are low? When would a patient benefit from systemic therapy but might not need his bladder removed? When is it that a patient with recently diagnosed prostate cancer can avoid any therapeutic intervention because the chances of disease progression are minimal?

“These are the things that as a pathologist interest me the most – not only who needs systemic therapy but who can we actually treat more conservatively,” Dr. Reuter says. “Hopefully they'll be the significant inroads in the next five years or so.”

RESEARCH SPOTLIGHT

The pathologist shares her latest research on two new screening approaches for pan-cancer targetable molecular events.



JACLYN HECHTMAN, MD

By Hope Cristol

At the 2018 United States & Canadian Academy of Pathology (USCAP) meeting in Vancouver, pathologist Jaclyn Hechtman, MD, spoke on a panel for Medscape Education. The topic was Evolving Diagnostics Standards in Characterizing Cancer, with an emphasis on testing treatment-naïve cancers for rare alterations that are targetable. It gave Dr. Hechtman an ideal opportunity to share some of her recently published work.

Dr. Hechtman is an assistant attending physician on the Gastrointestinal (GI) Pathology team and the Molecular Diagnostics Service.

Her primary research interest is in the molecular characterization of colorectal carcinomas. “Being that I practice both surgical and molecular pathology, I also participate in assay validation,” she says. “When collaborating with clinicians, I’m often the team member who selects the appropriate assay and/or interprets multiple different assays across surgical and molecular pathology.”

Dr. Hechtman has investigated under-represented driver alterations in colorectal carcinoma including 20q amplification (*Molecular Cancer Research*, 2017), SOX9 mutations (*Oncotarget*, 2016), recurrent AKT1

mutations (*Molecular Cancer Research*, 2015), and under-represented fusions and activating mutations (*Molecular Cancer Research*, 2016) in her time at MSK. However, at the USCAP/Medscape presentation in March, it was all about her two latest papers: one on pan-Trk immunohistochemistry for neurotrophic tyrosine receptor kinase (NTRK) fusions (*American Journal of Surgical Pathology*, 2017), and another on getting microsatellite instability (MSI) status from next-generation sequencing data (*Journal of Clinical Pathology Precision Oncology*, 2017).

NTRK FUSION SCREENING

Immunohistochemistry (IHC) has certain advantages over next-generation sequencing (NGS) of DNA or RNA, such as lower costs and faster turnaround time. There’s also the matter of expertise. It can be technically difficult to extract RNA and perform NGS, whereas IHC is widely used across pathology labs.

MSK oncologists David Hyman, MD, and Alexander Drilon, MD, recently led a clinical trial investigating the use of larotrectinib for NTRK-fusion positive cancers. The results showed “marked and durable antitumor activity,” (*New England Journal of Medicine*, 2018). As a collaborator in the study, Dr. Hechtman worked with the Diagnostic Molecular Pathology and Developmental IHC labs to explore the utility of pan-Trk IHC to detect these targetable NTRK fusions, which define certain rare cancers and are also present in low numbers in very common cancers. The results were promising:

- Pan-Trk IHC was positive in 20 of 21 cases with NTRK fusion transcripts confirmed by Archer fusion testing (sensitivity for transcribed fusions of 95%).
- 20 Archer-negative cases all had concordant pan-Trk IHC results (specificity for transcribed fusion of 100%).
- 2 cases with DNA level NTRK rearrangements with negative Archer results were also negative for pan-Trk IHC.

“Pan-Trk IHC makes screening for this particularly treatable fusion much faster and more accessible,” Dr. Hechtman says. “It also carries the benefit of protein-level analysis, which ensures that novel DNA level rearrangements are transcribed, expressed and likely to be functional and oncogenic.”

Although commercially available,

pan-Trk IHC isn’t widely used in surgical or molecular pathology – yet. The results of the recent larotrectinib trial for NTRK-fusion positive cancers will likely result in an increase in screening of driver negative cancers for NTRK fusions.

MICROSATELLITE INSTABILITY SCREENING

Microsatellite instability (MSI)/mismatch repair (MMR) status has several clinical implications, including response to immune checkpoint inhibitors and the potential need for additional testing for Lynch syndrome. That’s why the National Comprehensive Cancer Network recommends screening for all patients with colorectal cancer and for patients with uterine endometrioid cancer who are at risk for Lynch syndrome.

“MMR IHC and MSI PCR are the most commonly used assays in many labs. However, with next generation sequencing being performed in many of the advanced cancers at MSKCC, we decided to build MSI status testing into our NGS panel,” Dr. Hechtman says.

They turned to MSK-IMPACT and inferred MSI status from more than 12,000 solid tumors using MSIsensor, a program that reports the percentage of unstable microsatellites as a score.

The researchers found that obtaining MSI status from MSK-IMPACT is both possible and reliable. It also resulted in an unexpected number of rarer cancers with MSI-H status: 35% of all MSI-high tumors were not colorectal or uterine endometrioid carcinomas.

“This addition to MSK-IMPACT makes it possible for us to screen all patients who receive NGS testing for MSI-H status without additional testing,” Dr. Hechtman says. “If the patient’s tumor is MSI-H, there may be significant changes to patient management, including potential eligibility for immune checkpoint inhibitor therapy and discussions regarding further germline testing for Lynch syndrome.”

“MMR IHC and MSI PCR are the most commonly used assays in many labs. However, with next generation sequencing being performed in many of the advanced cancers at MSKCC, we decided to build MSI status testing into our NGS panel...”

- Jaclyn Hechtman, MD

Third Annual Symposium in
**TRANSLATIONAL
 RESEARCH
 IN PATHOLOGY**
 IN HONOR OF
WILLIAM GERALD MD, PHD



**POSTERS DISPLAYED AT THE THIRD ANNUAL
 SYMPOSIUM IN TRANSLATIONAL RESEARCH IN PATHOLOGY**

Alex, Travis, Rekhtman, Buonocore, Sauter - Pulmonary Pathology.

Histologic Features Predictive of Response to PD-1 Blockade in Patients with Non-small Cell Lung Carcinoma

Arias-Stella, Ladanyi, S. Dogan - Head and Neck Pathology.

Pathogenic SMARCA4 Mutations in Head and Neck and Thyroid Carcinomas are Rare

Arias-Stella, Lewis, Benayed, Soslow, Antonescu, Ladanyi, Chiang, Jungbluth - Gynecologic Pathology. *Novel PLAG1 Gene Rearrangement Distinguishes Uterine Myxoid Leiomyosarcoma from Other Uterine Myxoid Mesenchymal Tumors*

Bhanot, Roehrl - Quality Assurance. *The Precision Pathology Biobanking Center (PPBC) Experience at International IBBL Biobank Proficiency Testing*

Bhanot, Roehrl - Quality Assurance. *The Rapidly Growing Role of Pathology in Clinical Trials at a Major Cancer Center*

Chiang, Cotzia, Hechtman, Jungbluth, Murali, Soslow, Benayed, Ladanyi, Antonescu - Gynecologic Pathology. *NTRK Fusions Define a Novel Uterine Sarcoma Subtype with Features of Fibrosarcoma*

Cotzia, Al-Ahmadie, Chen, Gopalan, Sirintrapun, Tickoo, Reuter, Fine - Genitourinary Pathology. *Grade Group 2 Prostate Cancer with Poorly Formed Glands Alone on Needle Biopsy: Histologic Features and Pathologic Outcomes at Radical Prostatectomy*

Grabenstetter, Brogi, Wen - Breast Pathology. *Oncotype DX Recurrence Score in Multifocal/Multicentric Ipsilateral Invasive Breast Carcinomas*

Guo, Alex, Lin - Cytopathology. *Impact of the Paris System for Reporting Urinary Cytology Atypical Urothelial Cells*

Category at a Major Cancer Center

Gupta, Aron, Cheville, Hansel, Lowenthal - Genitourinary Pathology. *Female Urethral Carcinoma: Analysis of 29 Cases and Proposal for a New Staging System.*

Gupta, Chen, Al-Ahmadie, Sirintrapun, Fine, Berger, Tickoo, S. Dogan, Reuter, Gopalan - Genitourinary Pathology. *TERT Copy Number Alterations, Promoter Mutations and Rearrangements in Adrenocortical Carcinomas: Clinicopathologic and Molecular Analysis of 62 Cases*

Gupta, Zarei, Sukov - Genitourinary Pathology. *Clear Cell Renal Cell Carcinomas with PDGFRA/ KIT (4q12) Co-amplification and PDGFRB (5q32) Amplification.*

Hajiyeva, Edelweiss - Breast Pathology. *Frozen Section of Sentinel Lymph Nodes in 702 Breast Cancer Patients Treated with Neoadjuvant Chemotherapy*

Hanna, Grabenstetter, Ross, Tan - Breast Pathology. *Invasive Lobular Carcinoma with an Unusual Immunophenotypic Profile*

Jameel, Brogi, Ross, Weigelt, Reis-Filho, Wen - Breast Pathology. *Targeted Next Generation Sequencing Analysis of Metaplastic Breast Carcinoma*

Jelloul, Yabe, Y. Zhang, A. Dogan, Xiao - Hematopathology. *Extramedullary Plasmablastic Transformation of Plasma Cell Myeloma: Clinicopathologic Study of 10 Cases*

K. Park, Turashvili - Gynecologic Pathology. *Morphologic Patterns of Secondary Involvement of the Uterine Cervix by Non-Gynecologic Neoplasms*

Khattar, Jelloul, Y. Zhang, Arcila, Lu Wang, A. Dogan - Hematopathology. *t(14;18) Negative Inguinal Follicular*

Lymphoma is Characterized by Genetic Abnormalities of 1p36/ TNFRSF14 and 16p/CREBBP Regions

Kumar, Lewis, Roshal, A. Dogan - Hematopathology. *Hairy Cell Leukemia Expresses Programmed Death 1 (PD-1): A New Diagnostic Marker*

Lewis, Yao, Y. Zhang, Roshal, Xiao - Hematopathology. *Myeloid Neoplasms with Features of Both Myelodysplastic/ Myeloproliferative Neoplasm with Ring Sideroblasts and Thrombocytosis and Myelodysplastic Syndrome with Del (5q)*

Matsuda, Hanna, Grabenstetter, Brogi - Techniques. *Developing an Efficient Approach for the Assessment of Tumor Extension by Ex Vivo Imaging of Breast Specimens: A Pilot Study Using X-Ray Tomosynthesis with Histopathologic Correlation*

Mirsadraei, Chen, Reuter, Lin - Cytopathology. *Cytological Characteristics of Hereditary Leiomyomatosis and Renal Cell Carcinoma (HLRCC)-Associated Renal Cell Carcinomas*

Montecalvo, Alex, Sauter, J. Chang, Ladanyi, Antonescu, Travis, Rekhtman - Pulmonary Pathology. *SMARCA4 (BRG1) Deficiency in Lung Carcinomas Correlates with Poor Differentiation and Aggressive Clinical Behavior*

Muthukumarana, K. Park, Soslow, Chiang - Gynecologic Pathology. *BCOR Expression in Mullerian Adenosarcoma: A Potential Diagnostic Pitfall*

Roehrl, Hameed, Matsuda, Murray, Brogi - Informatics. *The Roles of Micro-Computed Tomography (CT) in Breast Pathology*

Sigel, Werneck Krauss Silva, Basturk, Klimstra, Tang - Cytopathology. *Cytologic Features of Well-Differentiated G3 Pancreatic Neuroendocrine Tumors*

T. Wang, Vakiani, Hechtman, Sigel - Gastrointestinal Pathology. *Histoarchitectural Pattern Does Not Distinguish IDH1 Mutant Intrahepatic Cholangiocarcinomas from Non-IDH1 Mutant Controls*

Turashvili, Chiang, Delair, K. Park, Soslow, Murali - Gynecologic Pathology. *BRAF Mutations and Expression of Anti-BRAF-V600E (VET) in Low-Grade Serous Tumors of the Ovary*

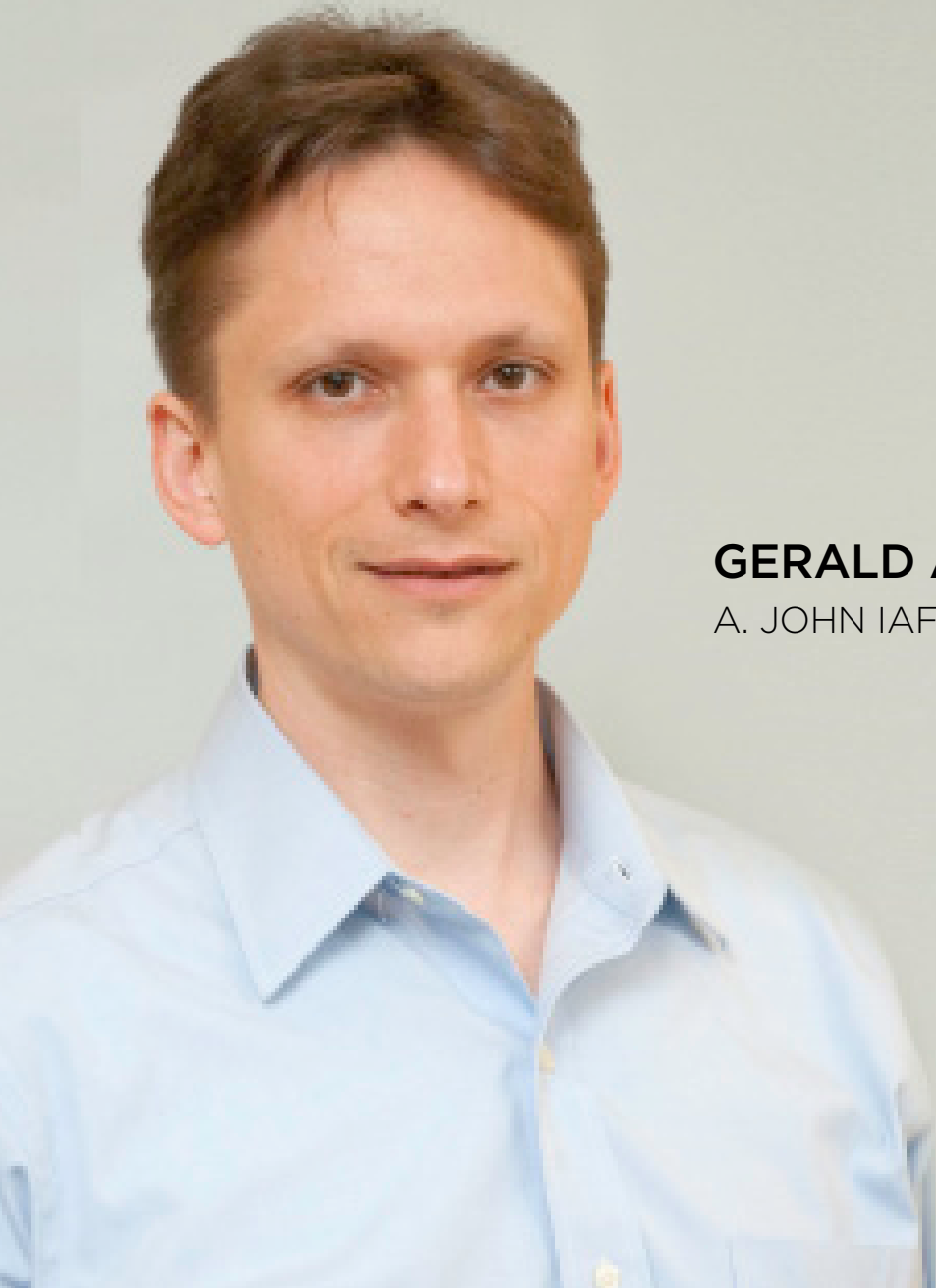Turashvili, Murali, Soslow - Gynecologic Pathology. *Prognostic Value of Clinicopathologic Variables in Synchronous Endometrial and Ovarian Carcinomas: Metastases or Independent Primary Tumors?*

Vanderbilt, Zehir, Arcila, S. Dogan, Ladanyi - Techniques. *Mining Large Panel Hybrid Capture-Based Clinical Next Generation Sequencing Data for Novel Virus Pathogen-tumor Associations Based on Mapping of Off-Target Reads to Viral Genomics*

Vyas, Basturk, Jungbluth, Askan, Klimstra, Shia - Gastrointestinal Pathology. *Immunohistochemical (IHC) and In-Situ Hybridization (ISH) Analysis of Common Hepatocellular Markers in Gastrointestinal Adenocarcinomas with Hepatoid Differentiation*

Vyas, Hechtman, Vakiani, Klimstra, Shia - Gastrointestinal Pathology. *In Colorectal Carcinoma (CRC), True Tumor Cell Staining for PD-L1 is Uncommon and Occurs in Sporadic Microsatellite-Unstable Tumors with Loss of MHC-I*

Werneck Krauss Silva, Al-Ahmadie, Chen, Gopalan, Sirintrapun, Tickoo, Reuter, Fine - Genitourinary Pathology. *Microscopic Bladder Neck Invasion Re-Visited: Correlation with Tumor Topography, Staging and Grading*



GERALD AWARD LECTUER
A. JOHN IAFRATE, MD, PHD

John Iafrate, MD, PhD, is the Director of the Center for Integrated Diagnostics at the Massachusetts General Hospital (MGH) and Professor of Pathology at Harvard Medical School. He is a native New Yorker and received his M.D. and Ph.D. degrees from Stony Brook University in 2000. He trained in anatomic and molecular genetic pathology at Brigham and Women's Hospital. During his postdoctoral work at the Brigham, John discovered copy number variations - copy number gains or losses of large genomic regions - as a novel source of human genetic diversity.

John joined the MGH pathology staff in 2005 and established the clinical laboratory for molecular diagnostics with the fundamental goal of developing high-throughput genetic screening approaches for all cancer patients. The molecular diagnostics laboratory expanded impressively under

his direction. His laboratory launched SNaPshot, a multiplex mutational profiling assay covering over 100 most common mutations in tumors to help direct novel targeted therapies. His laboratory also developed next-generation sequencing-based Anchored Multiplex PCR that detects gene fusion events from clinical specimens. Both of these techniques have been extensively used in the molecular diagnostics community.

John has also led major laboratory efforts particularly in the areas of lung and brain cancers as well as human germline genetics. He played a pivotal role in the recent development of small molecule kinase inhibitors for lung tumors with ALK and ROS1 tyrosine kinase rearrangements. His laboratory was also the first to discover tumor genetic heterogeneity in glioblastoma by studying gene amplification of receptor tyrosine kinases. John's interests transcend those related to

“ His commitment to personalized cancer care embodies a key principle of modern day medicine - of looking at disease through the genetic lens. ”

biological discoveries, and he has led studies that resulted in the development of novel molecular techniques to address unmet pathology and medical needs. For instance, John's continued research in the detailed structural analysis of copy number variations led to the development of FISH probes

based on deletion copy number variations to determine genetic identity in situ for applications in transplantation chimerism analysis. In addition, he has developed the Anchored Multiplex PCR method, which has come to become one of the 'gold standards' for fusion gene detection based on massively parallel sequencing.

John has been a superb educator and supportive mentor for countless pathology trainees, and a gifted speaker. He is a gifted and creative investigator whose selfless humility lends to numerous collaborative studies. His commitment to personalized cancer care embodies a key principle of modern day medicine - of looking at disease through the genetic lens.

- Jorge Reis-Filho, MD, PhD



NATIONAL MEDICAL LABORATORY PROFESSIONALS' WEEK 2018

This year's National Medical Laboratory Professionals' Week took place from April 22- April 28, 2018. The celebration included a wide variety of activities, events and educational lectures that served as a platform to showcase the impressive and vital work performed by our dedicated lab staff here at Memorial Sloan Kettering Cancer Center.

HERE WERE THE HIGHLIGHTS:

LECTURES

"THE CURIOUS CASES OF LABORATORY MEDICINE"

Drs. Patrick Erdman, Stephanie Forest and Lauren Moore

"DECODING COLORECTAL CANCER: THE IMPORTANT ROLE OF PATHOLOGY AND LABORATORY MEDICINE"

Dr. Jinru Shia

"THE 2018 MEDICAL LABORATORY PROFESSIONALS WEEK FEATURE LECTURE"

Keynote Speaker: Dr. Craig Thompson, MSKCC President and CEO

"CARS AND ARMORED CARS"

Dr. Renier Brentjens

"HOW DIGITAL PATHOLOGY CAN (AND WILL) TRANSFORM THE LABORATORY"

Dr. Matthew Hanna

LAB WEEK FAMILY FEUD CHALLENGE WINNERS:

1st Place:

Nana Mensah
Alejandra Pierre-Louis
Anita Yun
Paulo Salazar
Meiyi Wang

2nd Place:

Francine Johnson
Donna Marie Vastaro
Amanda Ly
Kalsang Shresthla
Shannon Kessy
Shannon Hall
Stanley Polich
Jum Chan
Alexander Gilbert

TALENT SHOW:

1st Place - Joel Polo, Mauricio Delgado and Steve Tulumba
2nd Place: Kuntal Kumar Serval
3rd Place: Sylvia W. Fedus

PHOTO CONTEST:

1st Place - Sean McNair
2nd Place - Nataly Bermeo
3rd Place - Kelsey Turner, Elise Feuer, Danielle Kehn
(Photos featured below)



FELLOWS' FEATURE

It has been a privilege for us to work with all of you this past year. Teaching fellows is certainly part of the core mission of our department, and it is very rewarding to work with bright pathologists who challenge our concepts and keep us sharp every day. We also understand that training here as a fellow involves a lot of hard work! You have shown outstanding dedication and professionalism - it is no understatement that our jobs and your jobs have been so intertwined, it is hard to conceive of them separately - it has been a true partnership. I hope that the experience you have gained - both from the unusual cases you encountered here and from the more routine case material - will help you transition from trainee to attending and develop the confidence you will need as you go out into the "real world" of independent practice. Wherever you go, you will carry this fellowship experience with you. Don't be surprised if, in your first few weeks of practice, your new senior colleagues seek your opinion about challenging cases. You have trained at Memorial, and everyone knows that you now bring a higher level of expertise to the diagnosis of cancer. So, with thanks, I bid you best wishes for your future, and I hope we will see all of you again at our alumni reunions and other professional events.

David Klimstra, MD
Chair, Department of Pathology; James Ewing Alumni Chair of Pathology

Congratulations and Best Wishes to all! You are an awesome group! Enjoyed working with you!

Meera Hameed, MD
Chief, Surgical Pathology Service

You have worked hard and endured a tough journey this past year. Congratulations- You made it! This class has truly been a gem. We are grateful for all the contributions you have made to our department and our patients. We are certain that you'll always look back on graduating from the Oncologic Surgical Pathology Fellowship as one of the major accomplishments in your life. We are proud to have you as Memorial alumni.

Melissa Murray, DO & Nora Katabi, MD

Done ✓ (at last).

Victor Reuter, MD
Vice Chair, Department of Pathology; Director, Genitourinary Pathology; Director, Genitourinary Pathology Fellowship; Director, Pathology Core Facility

FUTURE PLANS

ISABELLE CUI	Gastrointestinal Pathology Fellowship, University of Iowa
CHRISTIAN CURCIO	Bone and Soft Tissue Pathology Fellowship, MD Anderson
ANDREW GOLDEN	Thoracic Pathology Fellowship, MSKCC
LAURA FAVAZZA	Molecular Genetics Pathology Fellowship, University Pittsburgh Medical Center
MATTHEW HANNA	Attending Pathologist, MSKCC
PATRICK HENN	Gastrointestinal Pathology Fellowship, University Pittsburgh Medical Center
LIWEI JIA	Genitourinary Pathology Fellowship, MSKCC
UPASANA JONEJA	Gastrointestinal Pathology Fellowship, University of Pennsylvania
BRIE KEZLARIAN	Cytopathology Fellowship, MSKCC
DANIEL LEVITAN	Gynecologic and Perinatal Pathology Fellowship, NY Presbyterian/Weil Cornell
STEPHANIE MULLER	Cytopathology Fellowship, MSKCC
PALAWINNAGE VIDARSHI MUTHUKUMURANA	Cytopathology Fellowship, Baylor College of Medicine
MARYAM SHAHI	Attending Pathologist, University of Chicago
JAMES SOLOMON	Molecular Pathology Fellowship MSKCC
MONIKA VYAS	Gastrointestinal Pathology Fellowship, MSKCC
YOURAN ZOU	Attending Pathologist, Permanente Medical Group, CA
SABINA HAJIYEVA	Surgical Pathology Fellowship, John Hopkins
ZENA JAMEEL	Attending Pathologist, Lenox Hill
KANT MATSUDA	Attending Pathologist, George Washington University
DEEPU ALEX	Attending Pathologist, University of British Columbia
TIANHUA GUO	Attending Pathologist, CBL Path
LEILI MIRSDRAEI	Attending Pathologist, NYU Winthrop Hospital
BRIANNE DANIELS	Dermatopathologist, University of California San Diego
ALLEN MIRAFLORE	Dermatopathologist, Quest Laboratories, CA
TAO WANG	Attending Pathologist, Queen's University/Kingston Health Sciences Centre
YU-CHING PENG	Attending Pathologist, Koo Foundation Sun Yat-Sen Cancer Center
GULISA TURASHVILI	Attending Pathologist Mount Sinai Hospital Toronto
PALLAVI KHATTAR	Surgical Pathology Fellowship, MSKCC
FATIMA JELLOUL	Molecular Pathology Fellowship, MD Anderson
PRIYADARSHINI KUMAR	Advanced Hematopathology Fellowship, MSKCC
NATASHA LEWIS	Attending Pathologist, MSKCC
JAVIER ARIAS - STELLA	Attending Pathologist, City of Hope
JASON CHANG	Attending Pathologist, MSKCC
PAOLO COTZIA	Attending Pathologist, New York University
SOUNAK GUPTA	Genitourinary Pathology Fellowship, MSKCC
CHAD VANDERBILT	Attending Pathologist, MSKCC
VITOR WERNECK SILVA	Sabbatical Leave



FACULTY PUBLICATIONS

Al Efishat M, Attiyeh MA, Eaton AA, Gönen M, **Basturk O, Klimstra D**, D'Angelica MI, DeMatteo RP, Kingham TP, Balachandran V, Jarnagin WR, Allen PJ. Progression patterns in the remnant pancreas after resection of non-invasive or micro-invasive intraductal papillary mucinous neoplasms (IPMN). *Ann Surg Oncol*. 2018 Jun;25(6):1752-1759.

Alvarez MJ, Subramaniam PS, **Tang LH**, Grunn A, Aburi M, Rieckhof G, Komissarova EV, Hagan EA, Bodei L, Clemons PA, Dela Cruz FS, Dhall D, Diolaiti D, Fraker DA, Ghavami A, Kaemmerer D, Karan C, Kidd M, Kim KM, Kim HC, Kunju LP, Langel Ü, Li Z, Lee J, Li H, LiVolsi V, Pfragner R, Rainey AR, Realubit RB, Remotti H, Regberg J, Roses R, Rustgi A, Sepulveda AR, Serra S, Shi C, Yuan X, Barberis M, Bergamaschi R, Chinnaiyan AM, Detre T, Ezzat S, Frilling A, Hommann M, Jaeger D, Kim MK, Knudsen BS, Kung AL, Leahy E, Metz DC, Milsom JW, Park YS, Reidy-Lagunes D, Schreiber S, Washington K, Wiedenmann B, Modlin I, and Califano A. A precision oncology approach to the pharmacological targeting of mechanistic dependencies in neuroendocrine tumors. *Nature Genetics*. 2018.

Antonescu CR, Agaram NP, Sung YS, Zhang L, Swanson D, Dickson BC. A Distinct Malignant Epithelioid Neoplasm With GLI1 Gene Rearrangements, Frequent S100 Protein Expression, and Metastatic Potential: Expanding the Spectrum of Pathologic Entities With ACTB/MALAT1/PTCHI-GLI1 Fusions. *Am J Surg Pathol*. 2018;42(4):553-560.

Campbell JD, Yau C, Bowlby R, Liu Y, Brennan K, Fan H, Taylor AM, Wang C, Walter V, Akbani R, Byers LA, Creighton CJ, Coarfa C, Shih J, Cherniack AD, Gevaert O, Prunello M, Shen H, Anur P, Chen J, Cheng H, Hayes DN, Bullman S, Pedamallu CS, Ojesina AI, Sadeghi S, Mungall KL, Robertson AG, Benz C, Schultz A, Kanchi RS, Gay CM, Hegde A, Diao L, Wang J, Ma W, Sumazin P, Chiu HS, Chen TW, Gunaratne P, Donehower L, Rader JS, Zuna R, **Al-Ahmadie H**, Lazar AJ, Flores ER, Tsai KY, Zhou JH, Rustgi AK, Drill E, Shen R, Wong CK; Cancer Genome Atlas Research Network, Stuart JM, Laird PW, Hoadley KA, Weinstein JN, Peto M, Pickering CR, Chen Z, Van Waes C. Genomic, Pathway Network, and Immunologic Features Distinguishing Squamous Carcinomas. *Cell Rep*. 2018 Apr 3;23(1):194-212.e6.

Chiang S, Cotzia P, Hyman DM, Drilon A, Tap WD, **Zhang L, Hechtman JF**, Frosina D, **Jungbluth AA, Murali R, Park KJ, Soslow RA**, Oliva E, Iafrate AJ, Bayned R, **Ladanyi M, Antonescu CR**. NTRK Fusions Define a Novel Uterine Sarcoma Subtype With Features of Fibrosarcoma. *Am J Surg Pathol*. 2018;42(6):791-798. .

Cruz Paula A, Lozada JR, Blecua P, Muenst S, **Jungbluth AA**, Foschini MP, **Wen HY, Brogi E**, Palazzo J, Rubin BP, Ng CKY, Norton L, Varga Z, Ellis IO, Rakha EA, Chandralapaty S, **Weigelt B, Reis-Filho JS**. Recurrent hotspot mutations in HRAS Q61 and PI3K-AKT pathway genes as drivers of breast adenomyoepitheliomas. *Nat Commun*. 2018 May 8;9(1):1816.

Dickson BC, Sung YS, **Rosenblum MK, Reuter VE**, Harb M, Wunder JS, Swanson D, **Antonescu CR**. NUTM1 Gene Fusions Characterize a Subset of Undifferentiated Soft Tissue and Visceral Tumors. *Am J Surg Pathol*. 2018;42(5):636-645.

Fittall MW, Mifsud W, Pillay N, Ye H, Strobl AC, Verfaillie A, Demeulemeester J, **Zhang L**, Berisha F, Tarabichi M, Young MD, Miranda E, Tarpey PS, Tirabosco R, Amary F, Grigoriadis AE, Stratton MR, Van Loo P, **Antonescu CR**, Campbell PJ, Flanagan AM, Behjati S. Recurrent rearrangements of FOS and FOSB define osteoblastoma. *Nat Commun*. 2018;9(1):2150.

Geyer FC, Li A, Papanastasiou AD, Smith A, Selenica P, Burke KA, **Edelweiss M, Wen HC**, Piscuoglio S, Schultheis AM, Martelotto LG, Pareja F, Kumar R, Brandes A, Fan D, Basili T, Da Cruz Paula A, Lozada JR, Blecua P, Muenst S, **Jungbluth AA**, Foschini MP, **Wen HY, Brogi E**, Palazzo J, Rubin BP, Ng CKY, Norton L, Varga Z, Ellis IO, Rakha EA, Chandralapaty S, **Weigelt B, Reis-Filho JS**. Recurrent hotspot mutations in HRAS Q61 and PI3K-AKT pathway genes as drivers of breast adenomyoepitheliomas. *Nat Commun*. 2018 May 8;9(1):1816.

Geyer FC, Li A, Papanastasiou AD, Smith A, Selenica P, Burke KA, **Edelweiss M, Wen HC**, Piscuoglio S, Schultheis AM, Martelotto LG, Pareja F, Kumar R, Brandes A, Fan D, Basili T, Da Jordan EJ, Lowery MA, **Basturk O**, Allen PJ, Yu KH, Tabar V, Beal K, Reidy DL, Yamada Y, Janjigian Y, Abou-Alfa GK, O'Reilly EM. Brain Metastases in pancreatic ductal adenocarcinoma: assessment of molecular genotype-phenotype features – an entity with an increasing incidence? *Clin Colorectal Cancer*. 2018 Jun;17(2):e315-e321

Gucalp A, Zhou XK, Cook ED, Garber JE, Crew KD, Nangia JR, Bhardwaj P, **Giri DD**, Elemento O, Verma A, Wang H, Lee JJ, Vornik LA, Mays C, Weber D, Sepeda V, O'Kane H, Krasne M, Williams S, Morris PG, Heckman-Stoddard BM, Dunn BK, Hudis CA, Brown PH, Dannenberg AJ. A Randomized Multicenter Phase II Study of Docosahexaenoic Acid in Patients with a History of Breast Cancer, Premalignant Lesions, or Benign Breast Disease. *Cancer Prev Res (Phila)*. 2018 Apr;11(4):203-214.

Hissong E, Ramrattan G, Zhang P, et al. Gastric Carcinomas With Lymphoid Stroma: An Evaluation of the Histopathologic and Molecular Features. *The American Journal of Surgical Pathology*. 2018;42(4):453-462.

Intlekofer AM, Joffe E, Batlevi CL, Hilden P, He J, Seshan VE, Zelenetz AD, Palomba ML, Moskowitz CH, Portlock C, Straus DJ, Noy A, Horwitz SM, Gerecitano JF, Moskowitz A, Hamlin P, Matasar MJ, Kumar A, van den Brink MR, Knapp KM, Pichardo JD, Nahas MK, Trabucco SE, Mughal T, Copeland AR, Papaemmanuil E, Moarii M, Levine RL, **Dogan A**, Miller VA, Younes A. Integrated DNA/RNA targeted genomic profiling of diffuse large B-cell lymphoma using a clinical assay. *Blood Cancer J*. 2018 Jun 12;8(6):60. Iyengar NM, Chen IC, Zhou XK, **Giri DD**, Falcone DJ, Winston LA, Wang H, Williams S, Lu YS, Hsueh TH, Cheng AL, Hudis CA, Lin CH, Dannenberg AJ. Adiposity, Inflammation, and Breast Cancer Pathogenesis in Asian Women. *Cancer Prev Res (Phila)*. 2018 Apr;11(4):227-236.

Kao YC, Flucke U, Eijkelenboom A, Zhang L, Sung YS, Suurmeijer AJH, **Antonescu CR**. Novel EWSR1-SMAD3 Gene Fusions in a Group of Acral Fibroblastic Spindle Cell Neoplasms. *Am J Surg Pathol*. 2018;42(4):522-528.

Kao YC, Owosho AA, Sung YS, Zhang L, Fujisawa Y, Lee JC, Wexler L, Argani P, Swanson D, Dickson BC, Fletcher CDM, **Antonescu CR**. BCOR-CCNB3 Fusion Positive Sarcomas: A Clinicopathologic and Molecular Analysis of 36 Cases With Comparison to Morphologic Spectrum and Clinical Behavior of Other Round Cell Sarcomas. *Am J Surg Pathol*. 2018;42(5):604-615.

Kumar A, Vardhana S, Moskowitz AJ, Porcu P, **Dogan A**, Dubovsky JA, Matasar MJ, Zhang Z, Younes A, Horwitz SM. Pilot trial of ibrutinib in patients with relapsed or refractory T-cell lymphoma. *Blood Adv*. 2018 Apr 24;2(8):871-876.

Kuzu I, **Dogan A**. Immunohistochemical Biomarkers in Diagnosis of Hematolymphoid Neoplasms of Endocrine Organs. *Endocr Pathol*. 2018 Jun;29(2):176-188.

Laino ME, Ragucci M, Klimstra DS, Mannelli L. Hepatobiliary and Pancreatic: Primary acinar cell carcinoma of the liver showing good response to chemotherapy. *Journal of Gastroenterology and Hepatology*. 2018;33(5):977. Landgren O, Zeig-Owens R, Giricz O, Goldfarb D, Murata K, Thoren K, Ramanathan L, Hultcrantz M, **Dogan A**, Nwankwo G, Steidl U, Pradhan K, Hall CB, Cohen HW, Jaber N, Schwartz T, Crowley L, Crane M, Irby S, Webber MP, Verma A, Prezant DJ. Multiple Myeloma and Its Precursor Disease Among Firefighters Exposed to the World Trade Center Disaster. *JAMA Oncol*. 2018 Jun 1;4(6):821-827.

Lee SH, Hu W, Matulay JT, Silva MV, Owczarek TB, Kim K, Chua CW, Barlow LJ, Kandoth C, Williams AB, Bergren SK, Pietzak EJ, Anderson CB, Benson MC, Coleman JA, Taylor BS, Abate-Shen C, McKiernan JM, **Al-Ahmadie H**, Solit DB, Shen MM. Tumor Evolution and Drug Response in Patient-Derived Organoid Models of Bladder Cancer. *Cell*. 2018 Apr 5;173(2):515-528.e17.

Lewis, N., **Soslow R.A., Delair D., Park K., Chiang, S.**, et al. "ZC3H7B-BCOR High-Grade Endometrial Stromal Sarcomas: A Report of 17 Cases of a Newly Defined Entity." *Modern Pathology*, vol. 31, no. 4, 2018, pp. 674-684.

Lozada JR, Basili T, Pareja F, Alemar B, Paula ADC, Gualarte-Merida R, **Giri DD**, Querzoli P, Cserni G, Rakha EA, Foschini MP, **Reis-Filho JS, Brogi E, Weigelt B, Geyer FC**. Solid papillary breast carcinomas resembling the tall cell variant of papillary thyroid neoplasms (solid papillary carcinomas with reverse polarity) harbour recurrent mutations affecting IDH2 and PIK3CA: a validation cohort. *Histopathology*. 2018 Mar 30.

Mueller, J. J., **Soslow, R.A.** et al. "International Study of Primary Mucinous Ovarian Carcinomas Managed at Tertiary Medical Centers." *International Journal of Gynecological Cancer*, vol. 28, no. 5, 2018, pp. 915-924.

Ng SY, Yoshida N, Christie AL, Ghandi M, Dharia NV, Dempster J, Murakami M, Shigemori K, Morrow SN, Van Scoyk A, Cordero NA, Stevenson KE, Puligandla M, Haas B, Lo C, Meyers R, Gao G, Cherniack A, Louissaint A Jr, Nardi V, Thorner AR, Long H, Qiu X, Morgan EA, Dorfman DM, Fiore D, Jang J, Epstein AL, **Dogan A**, Zhang Y, Horwitz SM, Jacobsen ED, Santiago S, Ren JG, Guerlavais V, Annis DA, Aivado M, Saleh MN, Mehta A, Tsherniak A, Root D, Vazquez F, Hahn WC, Inghirami G, Aster JCh, Weinstock DM, Koch R. Targetable vulnerabilities in T- and NK-cell lymphomas identified through preclinical models. *Nat Commun*. 2018 May 22;9(1):2024.

Ng SY, Yoshida N, Christie AL, Ghandi M, Dharia NV, Dempster J, Murakami M, Shigemori K, Morrow SN, Van Scoyk A, Cordero NA, Stevenson KE, Puligandla M, Haas B, Lo C, Meyers R, Gao G, Cherniack A, Louissaint A Jr, Nardi V, Thorner AR, Long H, Qiu X, Morgan EA, Dorfman DM, Fiore D, Jang J, Epstein AL, **Dogan A**, Zhang Y, Horwitz SM, Jacobsen ED, Santiago S, Ren JG, Guerlavais V, Annis DA, Aivado M, Saleh MN, Mehta A, Tsherniak A, Root D, Vazquez F, Hahn WC, Inghirami G, Aster JCh, Weinstock DM, Koch R. Targetable vulnerabilities in T- and NK-cell lymphomas identified through preclinical models. *Nat Commun*. 2018 May 22;9(1):2024.

Pages F, Mlecnik B, Marliot F, Bindea G, Ou FS, Bifulco C, Lugli A, Zlobec I, Rau TT, Berger MD, Nagtegaal ID, Vink-Borger E, Hartmann A, Geppert C, Kolwelter J, Merkel S, Grutzmann R, Van den Eynde M, Jouret-Mourin A, Kartheuser A, Leonard D, Remue C, Wang JY, Bavi P, **Roehrl MHA**, Ohashi PS, Nguyen LT, Han S, MacGregor HL, Hafezi-Bakhtiari S, Wouters BG, Masucci GV, Andersson EK, Zavadova E, Vocka M, Spacek J, Petruzella L, Konopasek B, Ondr P, Skalova H, Nemejcova K, Botti G, Tatangelo F, Delrio P, Ciliberto G, Maio M, Laghi L, Grizzi F, Fredriksen T, Buttard B, Angelova M, Vasaturo A, Maby P, Church SE, Angell HK, Lafontaine L, Bruni D, El Sissy C, Haicheur N, Kirilovsky A, Berger A, Lagorce C, Meyers JP, Paustian C, Feng Z, Ballesteros-Merino C, Dijkstra J, van de Water C, van Lent-van Vliet S, Knijn N, Musina AM, Scripcariu DV, Popivanova B, Xu M, Fujita T, Hazama S, Suzuki N, Nagano H, Okuno K, Torigoe T, Sato N, Furuhashi T, Takemasa I, Itoh K, Patel PS, Vora HH, Shah B, Patel JB, Rajvik KN, Pandya SJ, Shukla SN, Wang Y, Zhang G, Kawakami Y, Marincola FM, Ascierto PA, Sargent DJ, Fox BA, and Galon J. International validation of the consensus Immunoscore for the classification of colon cancer: a prognostic and accuracy study. *Lancet*. 2018;391(10135):2128-2139.

Ren Q, Wang L, **Al-Ahmadie HA, Fine SW, Gopalan A, Sirintrapun SJ, Tickoo SK, Reuter VE, Chen YB**. Distinct Genomic Copy Number Alterations Distinguish Mucinous Tubular and Spindle Cell Carcinoma of the Kidney From Papillary Renal Cell Carcinoma With Overlapping Histologic Features. *Am J Surg Pathol*. 2018 Jun;42(6):767-777.

Ring, B. Z., **Murali R., Soslow R.A.**, et al. "Transducin-Like Enhancer of Split 3 (TLE3) Expression is Associated with Taxane Sensitivity in Nonserous Ovarian Carcinoma in a Three-Cohort Study." *Cancer Epidemiology Biomarkers and Prevention*, vol. 27, no. 6, 2018, pp. 680-688.

Scholz, S. L., **Murali R.**, et al. "NF1 Mutations in Conjunctival Melanoma." *British Journal of Cancer*, vol. 118, no. 9, 2018, pp. 1243-1247.

Sebastiano C, Gennaro L, **Brogi E**, Morris E, Bowser ZL, **Antonescu CR**, **Pareja F**, Brennan S, **Murray MP**. Benign vascular lesions of the breast diagnosed by core needle biopsy do not require excision. *Histopathology*. 2017 Nov;71(5):795-804.

Shen H, Shih J, Hollern DP, Wang L, Bowlby R, **Tickoo SK**, Thorsson V, Mungall AJ, Newton Y, Hegde AM, Armenia J, Sánchez-Vega F, Pluta J, Pyle LC, Mehra R, **Reuter VE**, Godoy G, Jones J, Shelley CS, Feldman DR, Vidal DO, Lessel D, Kulis T, Cárcano FM, Leraas KM, Lichtenberg TM, Brooks D, Cherniack AD, Cho J, Heiman DI, Kasaian K, Liu M, Noble MS, Xi L, Zhang H, Zhou W, Zenklusen JC, Hutter CM, Felau I, Zhang J, Schultz N, Getz G, Meyerson M, Stuart JM; Cancer Genome Atlas Research Network, Akbani R, Wheeler DA, Laird PW, Nathanson KL, Cortessis VK, Hoadley KA. Integrated Molecular Characterization of Testicular Germ Cell Tumors. *Cell Rep*. 2018 Jun 12;23(11):3392-3406.

Stolnicu, S. **Park, K.**, et al. "Diagnostic Algorithmic Proposal Based on Comprehensive Immunohistochemical Evaluation of 297 Invasive Endocervical Adenocarcinomas." *American Journal of Surgical Pathology*, 2018.

Turner SR, **Buonocore D**, Desmeules P, **Rekhtman N**, **Dogan S**, **Lin O**, **Arcila ME**, Jones DR, Huang J. Feasibility of endobronchial ultrasound transbronchial needle aspiration for massively parallel next-generation sequencing in thoracic cancer patients. *Lung Cancer*. 2018;119:85-90.

Turashvili G, **Brogi E**. Tumor Heterogeneity in Breast Cancer. *Front Med (Lausanne)*. 2017 Dec 8;4:227.

Turashvili G, Gonzalez-Loperena M, **Brogi E**, Dickler M, Norton L, Morrow M, **Wen HY**. The 21-Gene Recurrence Score in Male Breast Cancer. *Ann Surg Oncol*. 2018 Jun;25(6):1530-1535.

Verrill C, Perry-Keene J, Srigley JR, Zhou M, Humphrey PA, Lopez-Beltran A, Egevad L, Ulbright TM, **Tickoo SK**, Epstein JI, Compérat E, Berney DM; Members of the ISUP Testicular Tumor Panel. Intraoperative Consultation and Macroscopic Handling: The International Society of Urologic Pathology (ISUP) Testicular Cancer Consultation Conference Recommendations. *Am J Surg Pathol*. 2018 Jun;42(6):e33-e43.

Wang T, Stadler ZK, Zhang L, Weiser MR, **Basturk O**, **Hechtman JF**, **Vakiani E**, **Saltz LB**, **Klimstra DS**, **Shia J**. Immunohistochemical null-phenotype for mismatch repair proteins in colonic carcinoma associated with concurrent MLH1 hypermethylation and MSH2 somatic mutations. *Familial Cancer*. 2018;17(2):225-228.

Weinreb I, Bishop JA, Chiosea SI, Seethala RR, Perez-Ordóñez B, Zhang L, Sung YS, Chen CL, Assaad A, Olliai BR, **Antonescu CR**. Recurrent RET Gene Rearrangements in Intraductal Carcinomas of Salivary Gland. *Am J Surg Pathol*. 2018;42(4):442-452.

Wen HY, **Brogi E**. Lobular Carcinoma In Situ. *Surg Pathol Clin*. 2018 Mar;11(1):123-145.